

---

Electronic Thesis and Dissertation Repository

---

12-5-2017 5:00 PM

## A Biomechanical Study Examining The Subacromial Balloon Spacer and Superior Capsular Reconstruction in the Treatment of Massive, Irreparable Rotator Cuff Tears

Supriya Singh, *The University of Western Ontario*

Supervisor: Dr. George Athwal, *The University of Western Ontario*

Co-Supervisor: Dr. Jim Johnson, *The University of Western Ontario*

A thesis submitted in partial fulfillment of the requirements for the Master of Science degree in Surgery

© Supriya Singh 2017

Follow this and additional works at: <https://ir.lib.uwo.ca/etd>



Part of the [Orthopedics Commons](#)

---

### Recommended Citation

Singh, Supriya, "A Biomechanical Study Examining The Subacromial Balloon Spacer and Superior Capsular Reconstruction in the Treatment of Massive, Irreparable Rotator Cuff Tears" (2017). *Electronic Thesis and Dissertation Repository*. 5134.

<https://ir.lib.uwo.ca/etd/5134>

This Dissertation/Thesis is brought to you for free and open access by Scholarship@Western. It has been accepted for inclusion in Electronic Thesis and Dissertation Repository by an authorized administrator of Scholarship@Western. For more information, please contact [wlsadmin@uwo.ca](mailto:wlsadmin@uwo.ca).

## ABSTRACT

Rotator cuff tears are common tendon injuries and can be a major source of pain and disability. Massive, irreparable rotator cuff tears are a challenging surgical dilemma as currently there is no gold standard treatment algorithm. Multiple possible treatment options exist yet no clear guidelines for optimal surgical technique for this disorder have been established.

In this study, two new techniques described in the treatment of massive, irreparable rotator cuff tears were explored; the insertion of a subacromial balloon spacer and superior capsular reconstruction. Their ability to restore glenohumeral joint kinematics was examined in cadaveric specimens with surgically created massive, irreparable rotator cuff tears. Humeral head migration and functional abduction forces were the outcomes measured.

Both the subacromial balloon spacer and the superior capsular reconstruction were effective at restoring humeral head position at varying degrees of abduction as compared to the intact shoulder state. Functional abduction force was also restored with both surgical techniques. Finally, the subacromial balloon filled from 10-25 mL proved to be the most effective in restoring humeral head positioning. Further clinical studies need to be performed to determine if these results are reproducible in vivo as well as in the long term.

### **KEYWORDS**

Massive, irreparable rotator cuff tears, subacromial balloon spacer, superior capsular reconstruction, superior humeral head migration

## CO-AUTHORSHIP STATEMENT

- Chapter 1** Supriya Singh – sole author
- Chapter 2** Supriya Singh – study design, data collection, manuscript preparation  
Dan Langhor – study design, data collection and statistical analysis  
Jacob Reeves – study design, data collection and statistical analysis  
George Athwal – study design and manuscript preparation  
Jim Johnson – study design and manuscript preparation
- Chapter 3** Supriya Singh – study design, data collection, statistical analysis and manuscript preparation  
Dan Langhor – study design, data collection, and statistical analysis  
Jacob Reeves – study design, data collection and statistical analysis  
George Athwal – study design and manuscript preparation  
Jim Johnson – study design and manuscript preparation
- Chapter 4** Supriya Singh – sole author

## ACKNOWLEDGEMENTS

This project and thesis could not have been completed without the kind and generous support of many people.

Drs. Athwal and Johnson took me on as a Master's student and were excellent research supervisors. They guided me through this process unfailingly. They provided me with support both inside and outside of the lab and I cannot thank them enough for their encouragement and contributions to our project. I am grateful for their mentorship and guidance.

Dan Langhor and Jacob Reeves, both spent countless hours in the lab trouble shooting our study design, testing the specimens, collecting and analyzing our data. They woke up early in the mornings and even on holidays to help me complete testing. They are the most reliable and helpful colleagues anyone could ask for. I am so grateful for my time in the lab with them.

The Roth McFarlane Hand and Upper Limb Centre research laboratory was my home base for this project. I am grateful to all those that help maintain and help run the laboratory. Jordan O'Brien was always there to ensure we had the equipment needed and that our technology did not fail.

I would like to also extend my acknowledgement to the wrist team who worked in the laboratory and were our friendly adversaries who were testing simultaneously. Thank you for being the footsteps in the background pushing us forward to accomplish our goals.

This project could not have been completed without the generous donations and support from InSpace Balloon and Smith and Nephew. Both donated supplies for our surgical procedures and ensured testing went smoothly. I am grateful for their support in advancing our research.

I feel fortunate to have had the opportunity to complete a master's degree while undergoing orthopedic surgery residency training. The orthopedic department was supportive and protective of my research time to ensure I was able to complete my project.

The master of science in surgery program is run by Janice Sutherland. I am grateful to Janice for keeping me on track and ensuring I was supported throughout this process of completing my degree.

Finally, thank you to my mother and brother, Jyoti Singh and Amardeep Singh. My brother is one of my best friends and role models and my mom is the strongest woman I know and inspires me to be the best I can be. I would not be where I am today without the love and support from my family.

## TABLE OF CONTENTS

Abstract.....	i
Co-authorship Statement.....	ii
Acknowledgements .....	iii
Table of Contents.....	v
List of Tables.....	x
List of Figures.....	xi
Chapter 1.....	1
1 Introduction.....	1
1.1 The Shoulder.....	1
1.1.1 Osteology.....	2
1.1.1.1 Clavicle.....	3
1.1.1.2 Scapula.....	4
1.1.1.3 Humerus.....	6
1.1.2 Labrum, Capsule and Ligaments.....	8
1.1.3 Rotator Cuff Muscles and Dynamic Stabilizers of the Shoulder.....	10
1.1.3.1 Subscapularis.....	11
1.1.3.2 Supraspinatus.....	11
1.1.3.3 Infraspinatus and Teres Minor.....	11
1.1.3.4 Deltoid.....	12
1.1.3.5 Dynamic Stabilizers.....	12

1.2 Rotator Cuff Pathology.....	13
1.2.1 Overview of Rotator Cuff Pathology.....	13
1.2.2 Clinical Manifestation.....	14
1.2.3 Treatment.....	15
1.3 Massive, Irreparable Rotator Cuff Tears.....	17
1.3.1 Overview.....	17
1.3.2 Treatment Options.....	18
1.3.3 Superior Capsular Reconstruction.....	19
1.3.4 Subacromial Balloon Spacer.....	21
1.3.5 Surgical Dilemma.....	24
1.4 Thesis Rationale.....	25
1.5 Thesis Objectives.....	26
1.6 Thesis Hypotheses.....	27
1.7 Thesis Overview.....	28
1.8 References.....	29
Chapter 2.....	34
2 A Comparison of Superior Capsular Reconstruction to the Subacromial Balloon Spacer.....	34
2.1 Introduction.....	34
2.2 Materials and Methods.....	39
2.2.1 Cadaveric Specimen Preparation.....	39
2.2.2 Testing Protocol.....	41
2.2.3 Outcome Variables.....	47

2.2.4 Statistical Analysis.....	48
2.3 Results.....	49
2.3.1 Humeral Head Migration.....	49
2.3.1.1 The Effect of Abduction Angle on Humeral Head Migration.....	50
2.3.1.2 The Effect of Shoulder State on Humeral Head Migration.....	52
2.3.1.3 The Effect of Deltoid Load on Humeral Head Migration.....	52
2.3.2 Functional Abduction Force.....	53
2.3.2.1 The Effect of Abduction Angle on Functional Abduction Force.....	53
2.3.2.2 The Effect of Shoulder State on Functional Abduction Force.....	54
2.3.2.3 The Effect of Deltoid Load on Functional Abduction Force.....	55
2.4 Discussion.....	56
2.4.1 Shoulder State.....	56
2.4.2 Abduction Angle.....	58
2.4.3 Deltoid Load.....	61
2.4.4 Strengths and Limitations.....	63
2.5 Conclusions.....	65
2.6 References.....	66
Chapter 3.....	70



3 A Biomechanical Study of the Subacromial Balloon Spacer in the Treatment of Massive, Irreparable Rotator Cuff Tears.....	70
3.1 Introduction.....	70
3.2 Materials and Methods.....	74
3.2.1 Cadaveric Specimen Preparation.....	74
3.2.2 Testing Protocol.....	75
3.2.3 Outcome Variables.....	77
3.2.4 Statistical Analysis.....	78
3.3 Results.....	79
3.3.1 Anterior-Posterior Humeral Head Migration.....	79
3.3.1.1 Shoulder State.....	79
3.3.1.2 Abduction Angle.....	82
3.3.1.3 Deltoid Load.....	83
3.3.2 Superior-Inferior Humeral Head Migration.....	84
3.3.2.1 Shoulder State.....	84
3.3.2.2 Abduction Angle.....	89
3.3.2.3 Deltoid Load.....	91
3.4 Discussion.....	93
3.4.1 Anterior-Posterior Humeral Head Migration.....	93
3.4.2 Superior-Inferior Humeral Head Migration.....	96
3.4.3 Strengths and Limitations.....	98
3.5 Conclusion.....	99
3.6 References.....	101

Chapter 4.....	103
4.1 Conclusions.....	103
4.2 Summary of Chapter 2: A Comparison of Superior Capsular Reconstruction to the Subacromial Balloon Spacer.....	105
4.3 Summary of Chapter 3: A Biomechanical Study of the Subacromial Balloon Spacer.....	107
4.4 Future Directions.....	109
4.5 Summary of Conclusions.....	110
Appendix A Glossary of Terms.....	111
Appendix B Superior Capsular Reconstruction Technique Guide.....	116
Appendix C Subacromial Balloon Spacer Insertion Technique Guide.....	132
Curriculum Vitae.....	134

## LIST OF TABLES

Table 1.1	Subacromial Balloon Sizing and Recommended Inflation Volumes.....	21
Table 2.1	Subacromial Balloon Sizing and Inflation Volumes.....	43
Table 3.1	Anterior Humeral Head Displacement.....	81
Table 3.2	Superior-Inferior Humeral Head Migration.....	87
Table 3.3	Impact of Deltoid Force on Humeral Head Migration based on Abduction Angles.....	91
Table 3.4	Impact of Deltoid Force on Humeral Head Migration based on Shoulder States.....	92

## LIST OF FIGURES

Figure 1-1	Shoulder Joint .....	3
Figure 1-2	Anterior View of Scapula .....	5
Figure 1-3	Posterior View of Scapula .....	5
Figure 1-4	Anterior View of the Humerus .....	7
Figure 1-5	Sagittal View of Right Scapula .....	9
Figure 1-6	Anterior and Posterior View of Right Scapula with Rotator Cuff Muscles.....	10
Figure 1-7	Intact Rotator Cuff Muscles and Supraspinatus Tear.....	14
Figure 1-8	Various Primary Arthroscopic Rotator Cuff Repairs .....	16
Figure 1-9	Massive, Irreparable Rotator Cuff Tear of Right Shoulder.....	18
Figure 1-10	Superior Capsular Reconstruction .....	20
Figure 1-11	Subacromial Balloon Spacer .....	23
Figure 1-12	Subacromial Balloon Spacer Device .....	23
Figure 2-1	Radiographic Depiction of the Acromiohumeral Distance.....	35
Figure 2-2	Shoulder Simulator Setup.....	40
Figure 2-3	Massive, Irreparable Rotator Cuff Tear State.....	42
Figure 2-4	Subacromial Balloon Spacer Insertion Device.....	44
Figure 2-5	Superior Capsular Reconstruction Set Up.....	46
Figure 2-6	Superior Capsular Reconstruction in Cadaveric Specimen.....	46
Figure 2-7	Results of Humeral Head Migration at Varying Abduction Angles at 80 N of Deltoid Load.....	51

Figure 2-8	The Effect of Abduction Angle on Functional Abduction Force.....	54
Figure 2-9	The Effect of Shoulder State on Functional Abduction Force.....	55
Figure 2-10	Resultant Vector of Deltoid Muscle Forces.....	60
Figure 3-1	Subacromial Balloon Spacer.....	77
Figure 3-2	Anterior-Posterior Humeral Head Migration at 40 N Deltoid Load.....	79
Figure 3-3	Anterior-Posterior Humeral Head Migration at 80 N Deltoid Load.....	80
Figure 3-4	Superior-Inferior Humeral Head Migration Results at 40 N Deltoid Load.....	85
Figure 3-5	Superior-Inferior Humeral Head Migration Results at 80 N Deltoid Load.....	86

# Chapter 1

## Introduction

### Overview

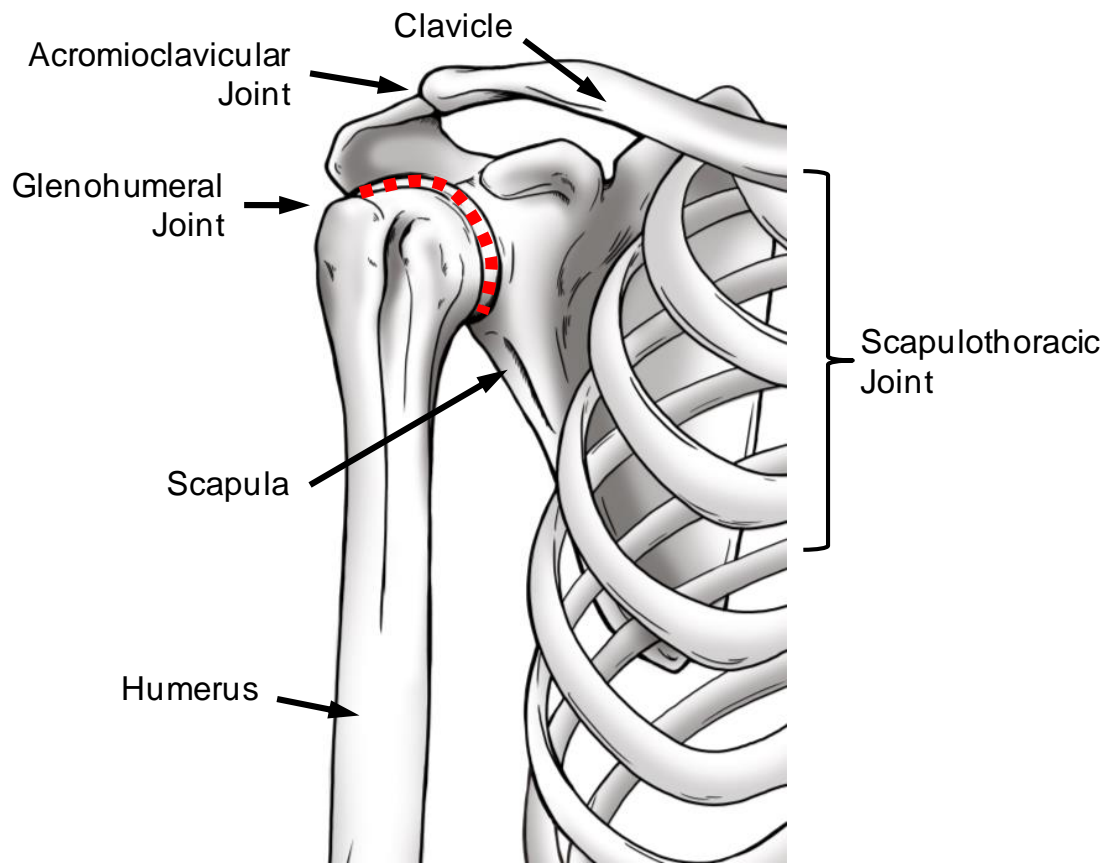
*The purpose of this thesis is to biomechanically assess two new treatment options for massive, irreparable rotator cuff tears. This chapter will review the basic glenohumeral joint anatomy in terms of osteology and musculature. Then, the pathology and clinical manifestation of rotator cuff tears will be described. A focus will be placed on the pathology of massive, irreparable rotator cuff tears and the surgical dilemma that they pose. A review of newer treatment options will be discussed including; superior capsular reconstruction and the subacromial balloon spacer. This introductory chapter will outline the background information and rationale for this thesis.*

## 1.1 The Shoulder

The shoulder, also known as the glenohumeral joint, is a multi-axial joint that sacrifices bony constraint for mobility. The glenohumeral joint is formed by the articulation of the glenoid fossa of the scapula and the humeral head of the humerus and forms a shallow ball and socket-like joint. The shoulder is the most mobile joint in the body and its range of motion includes forward flexion, extension, internal and external rotation, abduction, adduction and 360 degrees of circumduction (Tortora, 2003).

### 1.1.1 Osteology

The shoulder complex is made up of four major articulations (Figure 1-1). As mentioned above, the primary articulation is the glenohumeral joint between the glenoid fossa of the scapula and the humeral head of the humerus. Secondary articulations include the sternoclavicular joint between the sternum and the clavicle, the acromioclavicular joint between the acromion process of the scapula and the clavicle, and the scapulothoracic articulation between the scapula and the thoracic rib cage (Swarm, 2007). Three of these articulations are illustrated in Figure 1-1. The sternoclavicular joint is medial and not included in the figure.



**Figure 1-1: Shoulder Joint**

*This illustration demonstrates the primary bony structures of the glenohumeral joint (red dashed line).*

**1.1.1.1 The Clavicle**

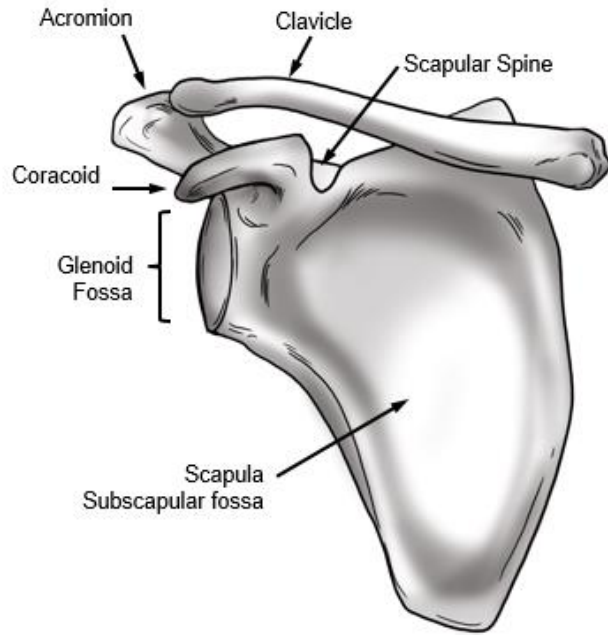
The clavicle is an “S Shaped” bone that connects the upper extremity to the axial skeleton. The clavicle has two articulations; medially it joins to the sternum to form the sternoclavicular joint and laterally it joins the acromion to form the acromioclavicular joint. The clavicle provides structural support to the glenohumeral joint with its muscular attachments of the deltoid, trapezius and pectoralis major.



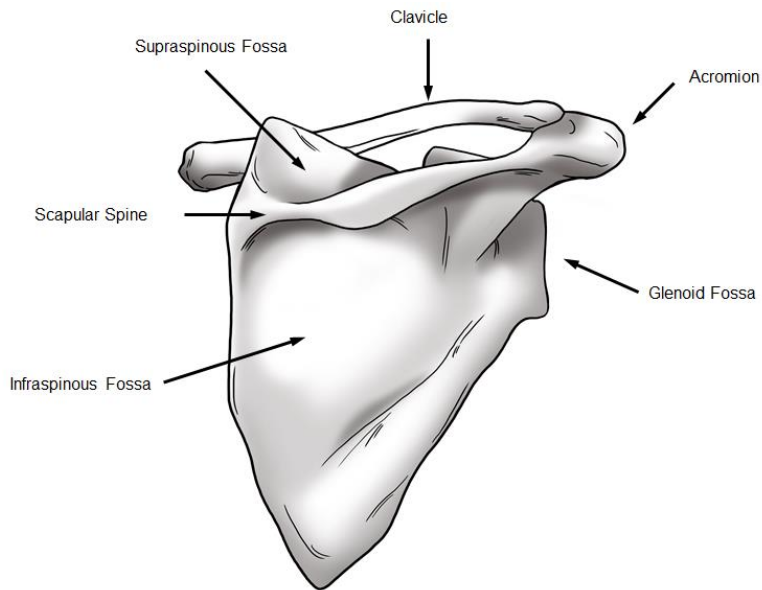
Additionally, the clavicle is stabilized by its attachment to the coracoid process of the scapula through the coracoclavicular ligaments (Terry, 2000.)

#### 1.1.1.2 The Scapula

The scapula is a triangular shaped bone that is the main origin of the rotator cuff musculature (Figure 1-2 & 1-3). Anteriorly, the scapular body comprises of the subscapular fossa and posteriorly, there is the supraspinous and the infraspinous fossae that are both above and below the scapular spine, respectively. These fossae are the origin of the rotator cuff muscles that help maintain shoulder joint motion and dynamic stability. In addition, the scapula is attached to the posterior rib cage through muscular attachments, which stabilizes the scapula, as well as the glenohumeral joint. The scapula has four main components; the glenoid fossa, the coracoid process, the acromion and the scapular spine. These processes are important sites for muscle and ligament attachments.



**Figure 1-2: Anterior View of Scapula**  
*Illustration of the osseous anatomy of the right scapula and clavicle*



**Figure 1-3: Posterior View of the Scapula**  
*Illustration of the osseous anatomy of the right scapula*

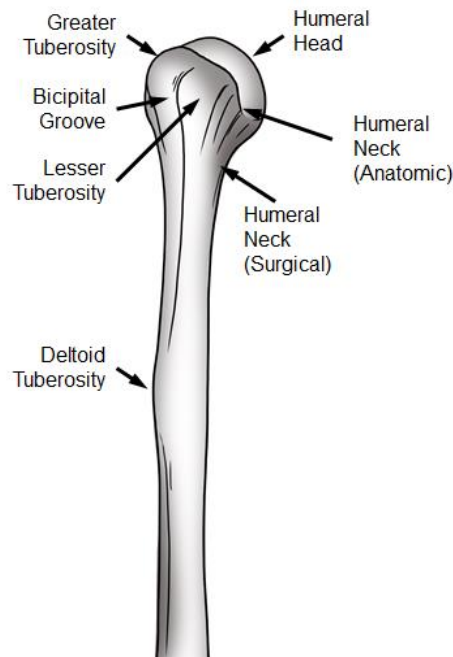
The glenoid fossa is a lateral projection of the scapula. It is a pear-shaped structure that articulates with the humeral head forming a synovial joint. The glenoid surface is covered with articular cartilage and at its periphery is outlined by a fibrocartilage ring; the glenoid labrum, which adds depth and stability to the glenoid fossa. The fossa is relatively shallow and is only one third to one quarter the size of the humeral head which contributes to the inherent instability of the joint (Terry, 2000).

The scapular spine process is a posterior structure that divides the supraspinous and the infraspinous fossae. The scapular spine is the attachment site for muscles such as the trapezius and the deltoid. The scapular spine projects laterally and terminates in the acromion process which is the most lateral projection of the scapula. The acromion is joined by the clavicle to form the acromioclavicular joint. Anteriorly, the coracoid process projects from the scapula serving as an important site for muscle and ligamentous attachment. The conjoint tendon, made up of the short head of the biceps, the coracobrachialis and the pectoralis minor tendon, originate from the coracoid process (Terry, 2000).

#### 1.1.1.3 The Humerus

The humerus is a long bone of the upper extremity (Figure 1-4). Proximally, the humeral head articulates with the glenoid fossa and contributes to the glenohumeral joint. Distally, the humerus articulates with the radius and the ulna forming the elbow

joint. For the purpose of this thesis, the focus will be on the proximal humeral anatomy. The humeral head is separated from the cylindrical humeral shaft by an anatomical and surgical neck. The anatomical neck is the border between the articular surface of the humeral head and the greater and lesser tuberosities. The tuberosities are bony protuberances that are important insertional sites for the rotator cuff muscles. The greater and lesser tuberosities are separated by the bicipital groove. This groove serves as the tract for the long head of the biceps, which runs proximally inserting above the glenoid fossa. Distally at the termination of the tuberosities is where the surgical neck is described and marks the separation of the proximal humerus and the humeral shaft. Below the surgical neck on the humeral shaft is the deltoid tuberosity, a prominent ridge where the deltoid muscle inserts (Swarm, 2007).



**Figure 1-4: Anterior View of the Humerus**

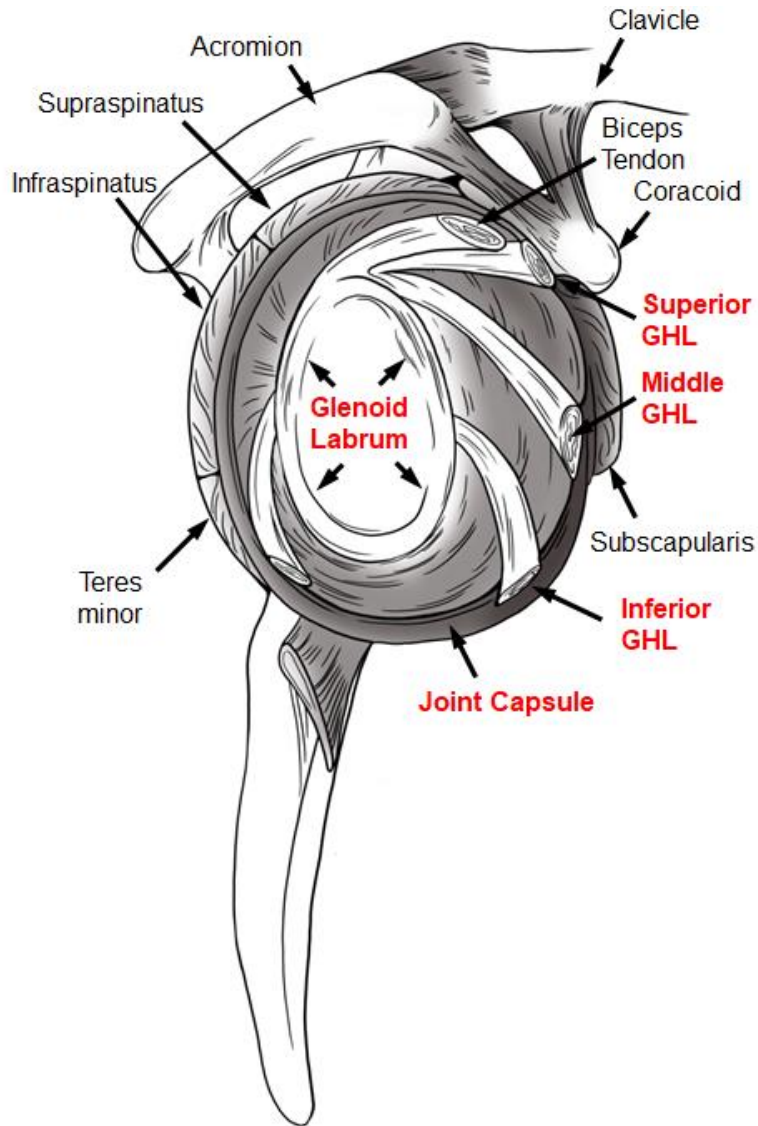
*Illustration of the osseous anatomy of the right proximal humerus*

### 1.1.2 Labrum, Capsule and Ligaments

The glenoid labrum as noted previously is a fibrocartilage ring that attaches circumferentially to the glenoid fossa. The role of the labrum is to help deepen the glenoid fossa, increase the congruency of the glenohumeral joint and help with force transmission across the glenohumeral joint. In addition, the labrum is an important site for the attachment of the glenohumeral ligaments and the long head of the biceps, which all add to joint stability (Swarm, 2007).

The joint capsule attaches from the scapular neck to the humeral neck. The normal thickness of the shoulder capsule is 1 to 5 mm. It has three distinct areas of thickening, known as the glenohumeral ligaments. These ligaments are important in maintaining static stability of the glenohumeral joint (Terry, 2000). The role of the superior glenohumeral ligament is to prevent inferior translation and external rotation of the humeral head (Terry, 2000). It runs parallel to the coracohumeral ligament and originates from the supraglenoid tubercle above the glenoid fossa to the lesser tuberosity on the humerus. The middle glenohumeral ligament is less structurally important and is variable in its anatomy (Terry, 2000). It originates from the supraglenoid tubercle and inserts on the lesser tuberosity as well. Finally, the inferior glenohumeral ligament originates from the inferior aspect of the glenoid (anterior and posterior band) and inserts into the inferior aspect of the humeral head. The anterior band serves an important role in prevention of anterior translation of the humeral head

(Burkhart, 2002). Figure 1-5 below illustrates the soft tissue anatomy described in this paragraph.

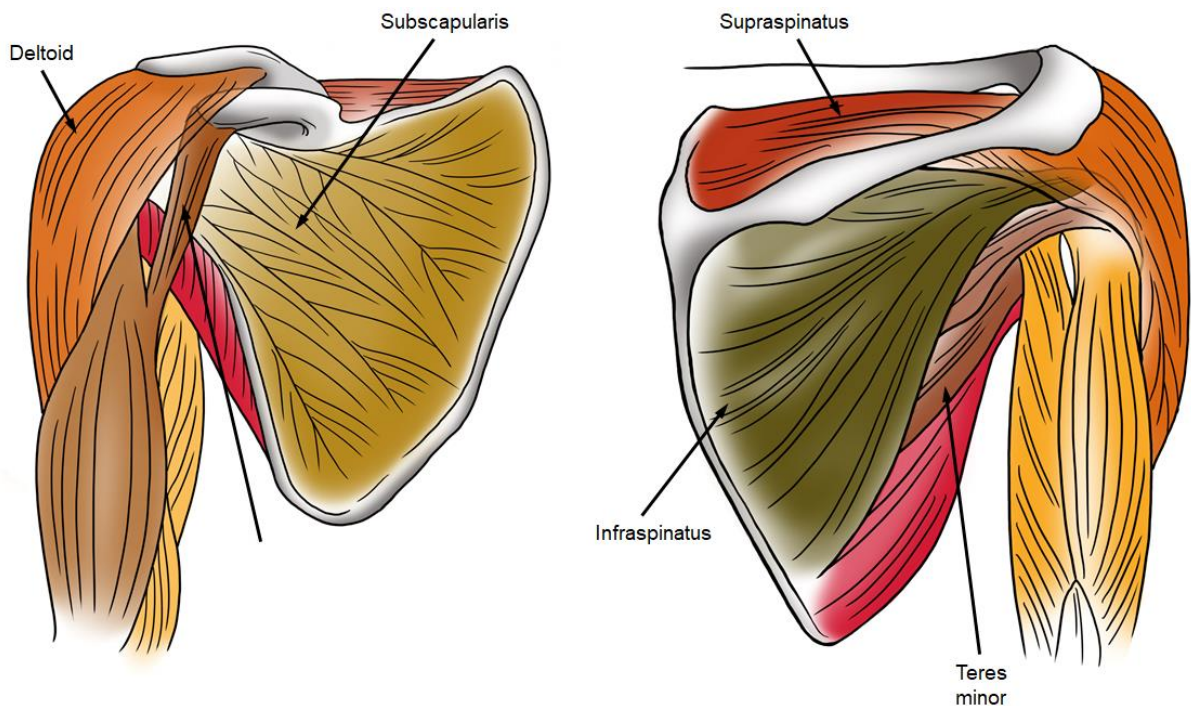


**Figure 1-5: Sagittal View of Right Scapula**

*Illustration of the soft tissue anatomy of the right scapula. The labels marked in red are the static stabilizers of the shoulder and include the joint capsule, glenohumeral (GHL) ligaments and labrum.*

### 1.1.3 Rotator Cuff Muscles and Dynamic Stabilizers of the Shoulder

The labrum, capsule and glenohumeral ligaments are all static stabilizers of the glenohumeral joint. Due to the innate incongruity between the glenoid fossa and the humeral head, the glenohumeral joint relies greatly on the surrounding ligaments and musculature for joint stability. Dynamic stability comes primarily from the rotator cuff muscles. There are four rotator cuff muscles that surround the joint capsule; the subscapularis (anterior), the supraspinatus (superior), the infraspinatus and the teres minor (posterior) (Figure1-6).



**Figure 1-6: Anterior (Left) and Posterior (Right) View of Right Scapula with Rotator Cuff Muscles**

*Illustration of the rotator cuff muscle anatomy of the right scapula.*

### 1.1.3.1 Subscapularis

The subscapularis originates from the subscapular fossa, which as previously described is on the anterior surface of the scapula. The muscle inserts onto the lesser tuberosity. It is innervated by both the upper and lower subscapular nerves and when activated it internally rotates the shoulder.

### 1.1.3.2 Supraspinatus

The supraspinatus, along with the superior capsule, acts as a roof, preventing superior humeral head migration. It originates from the supraspinous fossa, which lies above the scapular spine on the posterior aspect of the scapula. It inserts on the greater tuberosity. The supraspinatus is innervated by the suprascapular nerve and when activated helps initiate shoulder abduction.

### 1.1.3.3 Infraspinatus and Teres Minor

The infraspinatus and teres minor originate in the infraspinous fossa, which lies below the scapular spine on the posterior aspect of the scapula. Both muscles insert onto the posterior aspect of the greater tuberosity. The infraspinatus like the supraspinatus is innervated by the suprascapular nerve, whereas the teres minor is innervated by the axillary nerve. Both muscles when activated help with external rotation of the shoulder.



#### 1.1.3.4 Deltoid

The deltoid muscle is separated from the rotator cuff muscles by the subacromial bursa. The deltoid muscle is composed of three heads, anterior, middle and posterior, originating from the lateral clavicle, the acromion and the scapular spine, respectively. The three heads come together to insert along the deltoid tuberosity on the humeral shaft. The deltoid is innervated by the axillary nerve and causes forward flexion, abduction and extension by activating the anterior, middle and posterior head respectively.

#### 1.1.3.5 Dynamic Stabilizers

Together, the rotator cuff muscles and the deltoid help keep the humeral head centred in the glenoid fossa to allow normal range of motion and normal shoulder kinematics. The humeral head is kept centred in the glenoid concavity by the dynamic stabilizing and compressive forces caused by the contraction of the rotator cuff muscles (Abboud, 2002). Disruption of the rotator cuff tendons, will lead to humeral head migration and altered shoulder kinematics. Superior humeral head migration is caused by the loss of the superior structural support created by the supraspinatus, the upper aspect of the infraspinatus tendon as well as the superior joint capsule. Superior humeral head migration leads to a decreased subacromial space and over time can cause joint degeneration and symptoms such as pain, stiffness and disability.

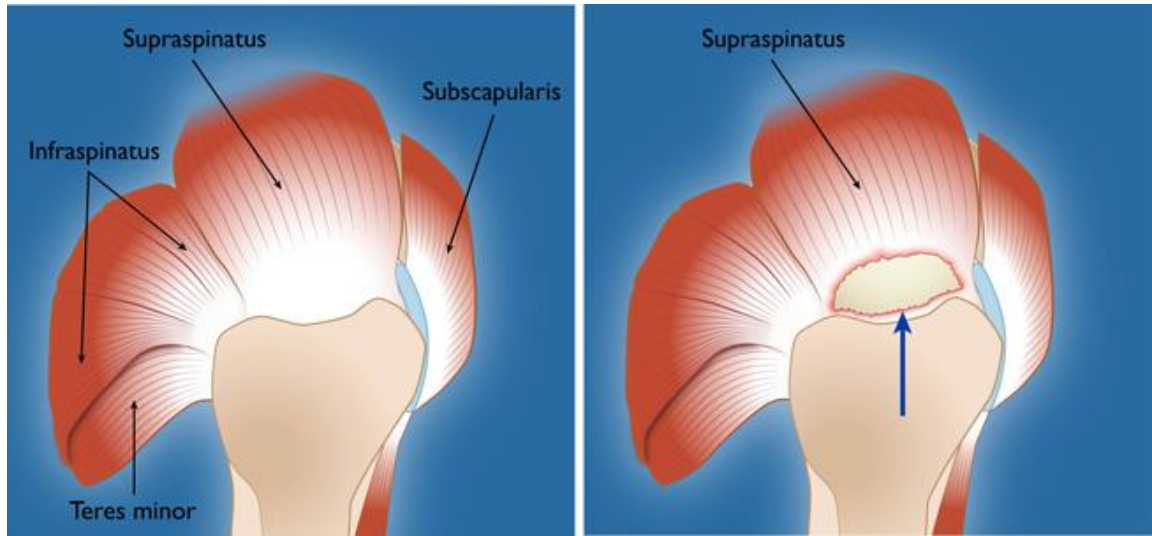
## 1.2 Rotator Cuff Pathology

### 1.2.1 Overview of Rotator Cuff Pathology

Rotator cuff tears can be a major source of pain and disability in our population. These injuries are the most common tendon injuries seen in orthopedics patients, affecting approximately 50% of individuals over the age of 60, with the incidence increasing with age (Savarese, 2012). Rotator cuff tears can occur from an acute traumatic injury such as a fall or dislocation and can occur from normal day to day “wear and tear”. In younger patients, it is more common to see an acute traumatic tear and in the older patients, rotator cuff tears are usually from chronic intrinsic degeneration. Rotator cuff pathology can present as a spectrum from subacromial impingement to tendonitis to partial or full thickness tears to arthropathy secondary to rotator cuff tears (St.Pierre, 2015).

The most common type of rotator cuff tear seen in orthopedic clinics is the chronic degenerative tear. The exact etiology is unknown, however certain risk factors such as advanced age, smoking, hypercholesterolemia and a positive family history may contribute to rotator cuff tendinopathy. The most common rotator cuff tendon affected during a tear is the supraspinatus tendon (Via, 2013) (Figure 1-7). The tendons involved depend on the size of the tear and whether they extend anteriorly (into the subscapularis tendon) or posteriorly (into the infraspinatus and teres minor tendons). Rotator cuff tears are classified according to which tendons are involved, the size of the tear, the thickness of the tear, the location and the shape of the tear. In addition, there are radiographic classifications that

describe rotator cuff tears based on their magnetic resonance imagine (MRI) appearance of muscle atrophy and fatty infiltration (St.Pierre, 2015).



**Figure 1-7: Intact Rotator Cuff Muscles (Left) and Supraspinatus Tear (Right)**  
*Illustration of the rotator cuff muscle anatomy of the right shoulder inserting onto the footprint (<http://orthoinfo.aaos.org/topic.cfm?topic=a00064>).*

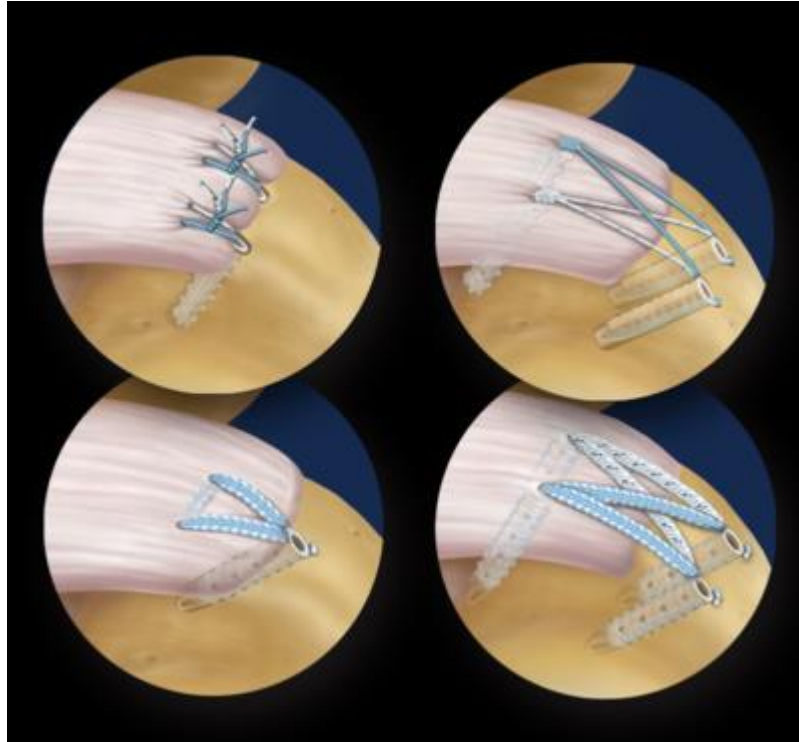
### 1.2.2 Clinical Manifestation

Regardless of the etiology or the type of rotator cuff tear, most patients with rotator cuff pathology present with similar symptoms, shoulder pain usually exacerbated by overhead activity, night pain and often associated loss of range of motion. There are specific physical exam maneuvers dedicated to isolate which rotator cuff tendon is involved, but patients often have non specific pain and diffuse symptoms and isolating the tendon can be challenging on physical exam alone (Via, 2006). Based on history

and physical examination, if the suspicion for a rotator cuff tear is present, further investigations using imaging modalities (ultrasound or MRI) can be helpful.

### 1.2.3 Treatment

The treatment of symptomatic rotator cuff tears depends on multiple factors including both patient factors and rotator cuff tear factors. The patient's age, activity level and work are important considerations. The mechanism of the tear and the characteristics of the tear are important to determine if a tear is surgically repairable (Burkhart, 2006). Regardless of the type of tear, the majority of rotator cuff tears are treated initially with non-operative management in the form of physical therapy, anti-inflammatories and possibly corticosteroid injections. Operative interventions are considered when non-operative measures fail and include subacromial decompression and debridement of the tear, rotator cuff repair (arthroscopic or open), tendon transfers, or even reverse total shoulder arthroplasty for large, irreparable tears with glenohumeral arthritis (Pedowitz, 2011). During primary repair of rotator cuff tendons, the end of the torn tendon is brought back to the footprint on the greater tuberosity of the humerus using suture anchors (Figure 1-8).



**Figure 1-8: Various Primary Arthroscopic Rotator Cuff Repairs**

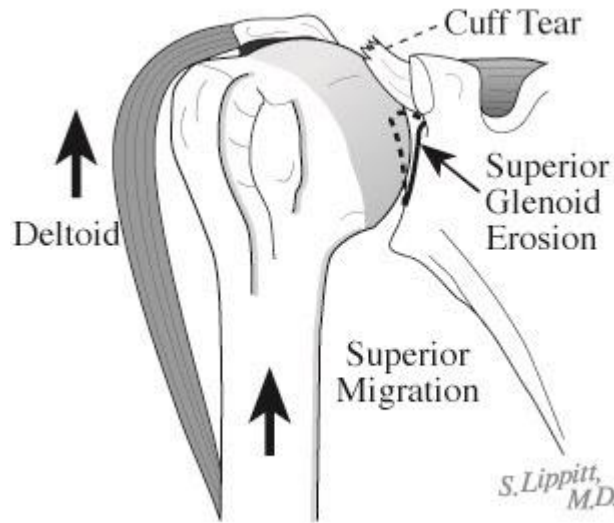
*Illustration demonstrating 4 different suture anchor techniques for primary rotator cuff tears. Suture anchors are inserted into the footprint of greater tuberosity on humerus (<https://www.arthrex.com/shoulder/rotator-cuff-repair>).*

A tear is deemed massive and irreparable when the tendon cannot be primarily repaired because it cannot be mobilized back to the footprint due to the large size of the tear and the degree of tendon retraction. The management of massive, irreparable rotator cuff tears is the main focus of this thesis.

## 1.3 Massive, Irreparable Rotator Cuff Tears

### 1.3.1 Overview

A massive, irreparable rotator cuff tear by definition is a tear greater than five centimetres, involving two or more tendons (Gerber, 2000). The irreparable nature of these tears is defined by the fact that the rotator cuff tendon cannot physically be repaired back to the footprint on the greater tuberosity of the humerus (Gerber, 2011). The incidence of massive, irreparable rotator cuff tears ranges from 7-22% (Moore, 2006). Patients with massive, irreparable rotator cuff tears will experience pain and disability, not dissimilar to those with simple rotator cuff tears, however, radiographically, patients with massive, irreparable rotator cuff tears, have superior humeral head migration and reduced acromiohumeral distance of less than 7mm (Normal 8-12 mm) (Ellman, 1986). With increasing superior humeral head migration, there is a decrease in the subacromial space and that is clinically manifested by reduced range of motion, reduced shoulder function, and pain (Figure1-9). The goals of treatment are then simple, prevent superior humeral head migration and restore glenohumeral joint kinematics to produce a painfree shoulder with return of range of motion. Unfortunately, surgical treatment is challenging for massive, irreparable rotator cuff tears as the tendons are retracted and inelastic, there is significant muscle atrophy and fatty infiltration. Currently, there is no gold standard treatment in the management of massive, irreparable rotator cuff tears.



**Figure 1-9: Massive, Irreparable Rotator Cuff Tear of Right Shoulder**

*Illustration demonstrating superior humeral head migration secondary to massive, irreparable rotator cuff tear (<http://shoulderarthritis.blogspot.ca/2011/08/>).*

### 1.3.2 Treatment Options

There are a variety of treatment options proposed for the management of massive, irreparable rotator cuff tears. Arthroscopic treatment options include simple subacromial debridement, with biceps tenotomy, partial rotator cuff tendon repairs, tuberopecty, interpositional graft placement, and suprascapular nerve ablation. Open treatment options include tendon transfers, hemiarthroplasty, and reverse total shoulder arthroplasty (Anley, 2014). These procedures all vary in terms of outcome, degree of invasiveness, and complication rates. Although each treatment has the goal of reducing pain and improving function, none alone, has proven to be the gold standard. The controversy and complexity of treating massive, irreparable rotator cuff tears is that no

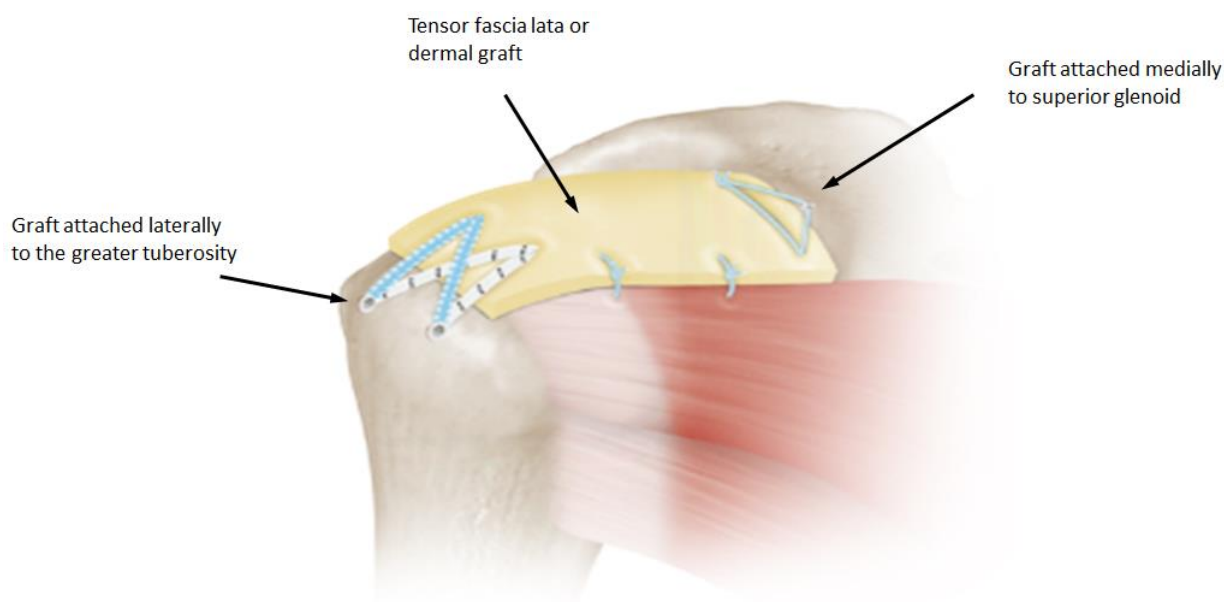
treatment option is ideal at restoring glenohumeral joint kinematics. In addition, in a young patient, with no glenohumeral joint arthritis, a reverse total shoulder arthroplasty is not an ideal treatment option. Recently, two new treatment options have been proposed for the management of massive, irreparable rotator cuff tears; superior capsular reconstruction and insertion of a subacromial balloon spacer.

### 1.3.3 Superior Capsular Reconstruction

The superior capsule of the glenohumeral joint acts as the static roof preventing superior humeral head migration in an intact shoulder. It lies on the undersurface of the supraspinatus and infraspinatus tendons and its main role is providing superior stability to the glenohumeral joint (Mihata, 2012). In the setting of a massive, irreparable rotator cuff tear, the superior capsule is disrupted. A new arthroscopic technique for superior capsular reconstruction was proposed by Mihata *et al.* to prevent superior humeral head migration and prevent subacromial impingement for massive, irreparable rotator cuff tears (Figure 1-10). The superior capsule is reconstructed using a dermal or tensor fascia lata graft (approximately 6-8mm in thickness). The technique includes attaching the graft medially to the superior aspect of the glenoid and laterally to the greater tuberosity. The graft is fixed to the bone on either side using suture anchors. In addition, the graft is sutured posteriorly to the infraspinatus with side to side sutures. A cadaveric study was performed by Mihata, *et al.* in 2012 concluding that superior capsular reconstruction completely restored superior stability of the



glenohumeral joint. In 2012, Mihata, *et al*, also published a clinical trial; a retrospective review between 2007 and 2009 of 24 patients with massive, irreparable rotator cuff tears that had undergone arthroscopic superior capsular reconstruction by a single surgeon. The average follow up was 34.1 months and the majority of patients showed a significant improvement in clinical scores as well as range of motion post operatively. Radiographically, the acromiohumeral distance improved significantly as well. Finally, 83.3% of the patients had an intact graft with no progression of osteoarthritis at the glenohumeral joint. In summary, both cadaveric and early clinical studies have shown promising results for superior capsular reconstruction by Mihata's group.



**Figure 1-10: Superior Capsular Reconstruction**

*Illustration demonstrating superior capsular reconstruction of the left shoulder.*

### 1.3.4 Subacromial Balloon Spacer

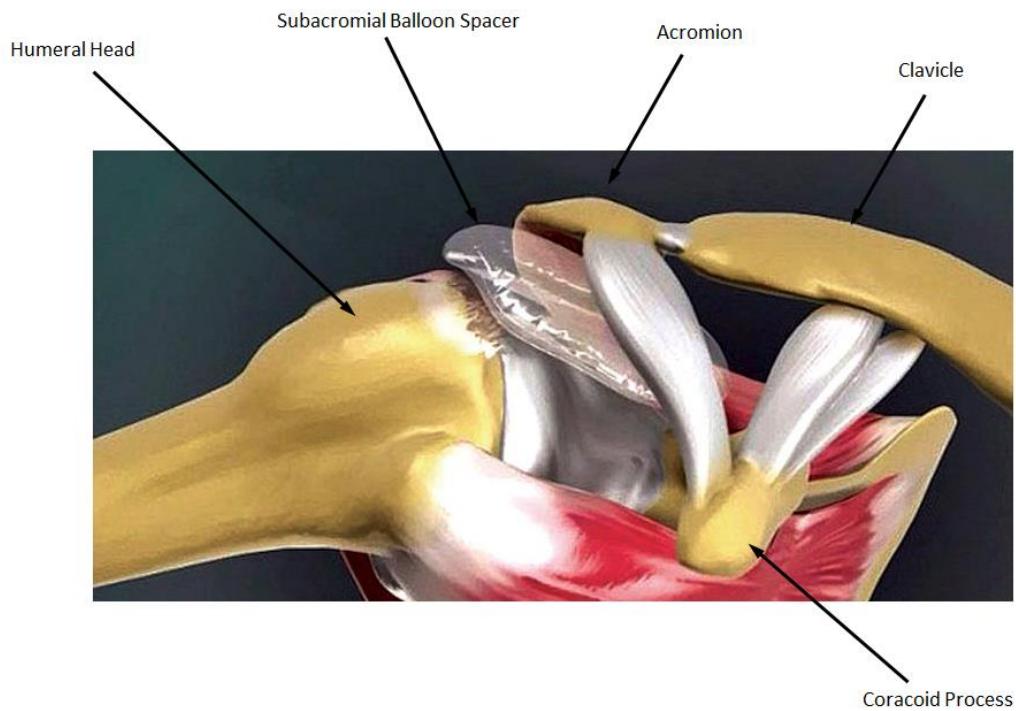
Another recent innovation in the treatment of massive, irreparable rotator cuff tears is the insertion of a subacromial balloon spacer (Figure 1-11 and 1-12). The InSpace Balloon was proposed as an arthroscopically inserted biodegradable spacer that is inserted between the acromion and humeral head to help depress the humeral head and prevent subacromial impingement in the setting of massive, irreparable rotator cuff tears (Savarese, 2012). The insertion technique involves a standard arthroscopic debridement of the subacromial space with a bursectomy, followed by measuring the subacromial space size from the lateral border of the acromion to the superior aspect of the glenoid rim for balloon sizing (Table 1.1). Once the appropriate sized balloon is selected, it is inserted in the subacromial space via a direct lateral portal. The balloon is inserted and inflated with saline. The only contraindications to this procedure would include active infections or allergies to the device material.

<b>Subacromial Space Size</b>	<b>Balloon Size</b>	<b>Width of Balloon (mm)</b>	<b>Length of Balloon (mm)</b>	<b>Recommended Volume of Balloon (mL)</b>
< 4 cm	Small	40	50	9-11
4-5 cm	Medium	50	60	14-16
> 5 cm	Large	60	70	23-25

**Table 1.1: Subacromial Balloon Sizing and Recommended Inflation Volumes**

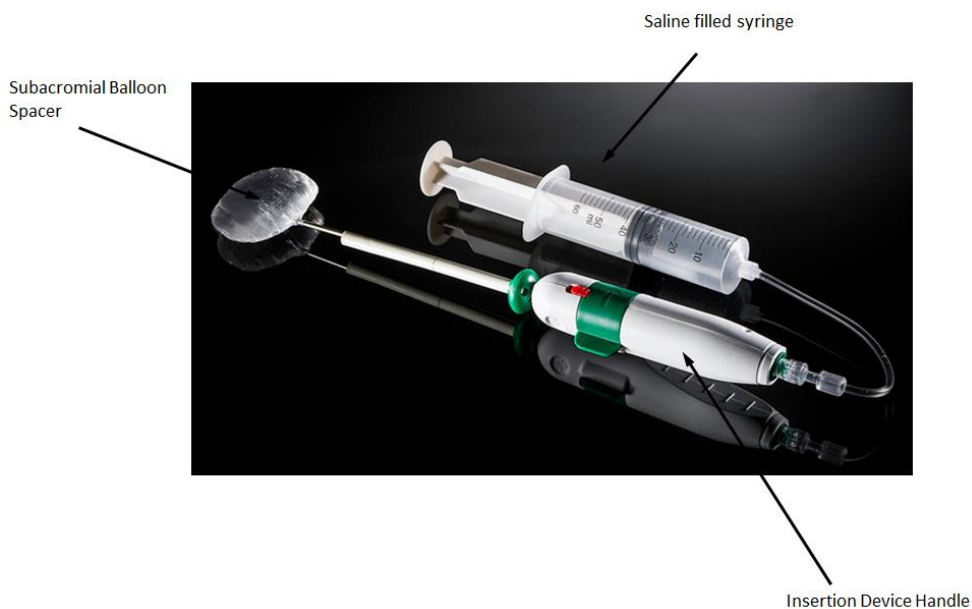
*This table outlines manufacturer recommendations for the appropriate balloon size selection and dimensions, as well as the inflation volume based on the subacromial size measurement.*

Savarese and Romeo described this surgical technique in 2012, and Gervasi, *et al.* described it again in 2014. Senekovic *et al.* published two clinical prospective case series; one with 3 year follow up and the other with 5 year follow up. These were small studies with 20 patients (11 male and 9 female, average age 70) that showed clinically significant improvement in shoulder function scores, improvement in strength and range of motion at the 5 year follow up mark (Senekovic, 2016). However, no biomechanics studies have been undertaken for the subacromial balloon spacer, even though early clinical studies show promising results. There is level 4 evidence that arthroscopic insertion of a subacromial balloon spacer is a low risk and simple procedure that improves shoulder function.



**Figure 1-11: Subacromial Balloon Spacer**

*Illustration demonstrating the subacromial balloon spacer in the right shoulder (<http://orthospace.co.il/professional/how-does-it-work/>).*



**Figure 1-12: Subacromial Balloon Spacer Device**

<https://www.israel21c.org/new-implant-eases-rotator-cuff-pain/>

### 1.3.5 Surgical Dilemma

The management of massive, irreparable rotator cuff tears is a surgical challenge. A reverse total shoulder arthroplasty is an effective management technique for the elderly with evidence of glenohumeral joint arthritis. Arthroplasty surgery is avoided in young patients with no arthritis to prevent unnecessary joint surface destruction and high surgical risks and complications. In addition, the longevity of arthroplasty implants is unknown and thus not an ideal option in this patient. This encourages scientists and surgeons to come up with alternative treatment options. The two current popular alternatives being considered are the superior capsular reconstruction and the subacromial balloon spacer. A variety of options exist, however there is no consensus on preferred surgical technique. Treatment options are the most controversial in the younger patients with massive, irreparable rotator cuff tears and with minimal glenohumeral joint arthritis.

## 1.4 Thesis Rationale

The surgical management of massive, irreparable rotator cuff tears is challenging. There is currently no ideal treatment and two new techniques have been proposed in the management of massive, irreparable rotator cuff tears. The literature review on these techniques has only level 4 evidence, showing early positive clinical results for both superior capsular reconstruction and insertion of a subacromial balloon spacer. Biomechanics studies have been done with respect to the superior capsular reconstruction, however, there have been no biomechanics studies done for the subacromial balloon spacer.

The purpose of this thesis is to examine both of these techniques at a biomechanical level in cadaveric specimens. This thesis encompasses two main studies. The first study will directly compare superior capsular reconstruction and the subacromial balloon spacer in their ability to restore glenohumeral joint kinematics. The second study will focus on the subacromial balloon spacer alone and the impact of different fill volumes on its ability to function as a device to restore humeral head position. These studies will yield important information in guiding future treatment of massive, irreparable rotator cuff tears.

## 1.5 Thesis Objectives

The objectives of this thesis are to examine the two new techniques in the treatment of massive, irreparable rotator cuff tears in cadaveric specimens.

The primary objectives of this thesis are:

1. To compare superior capsular reconstruction and the subacromial balloon spacer in their ability to prevent superior humeral head migration (Chapter 2).
2. To compare superior capsular reconstruction and the subacromial balloon spacer in their impact on functional abduction forces (Chapter 2).
3. To examine the subacromial balloon spacer in its ability to function as a device; comparing fill volumes and their ability to prevent humeral head translation (Chapter 3).

## 1.6 Thesis Hypotheses

The hypotheses of this thesis based on the objectives are:

1. Both superior capsular reconstruction and the subacromial balloon spacer will restore humeral head position to the native state at lower shoulder abduction angles. At higher abduction angles, the subacromial balloon spacer will restore humeral head position better than the superior capsular reconstruction (Chapter 2).
2. The functional abduction forces will be lower in the torn state and restored with both superior capsular reconstruction and with the subacromial balloon spacer as compared to the native state (Chapter 2).
3. Optimal balloon fill volumes will be important to maintaining humeral head position. Overinflation or underinflation of the subacromial balloon spacer will lead to suboptimal humeral head positioning in the glenoid fossa and lead to altered shoulder kinematics (Chapter 3).



## 1.7 Thesis Overview

This thesis examines the biomechanics of the superior capsular reconstruction technique and the subacromial balloon spacer for the treatment of massive, irreparable rotator cuff tears. The first chapter is an overview of the basic anatomy, as well as, a literature review of massive, irreparable rotator cuff tears and these two new techniques. The second chapter is focused on the biomechanical comparison of the superior capsular reconstruction technique and the subacromial balloon spacer in their ability to depress the humeral head and their impact on functional abduction force. The third chapter is solely focused on the biomechanics of the subacromial balloon spacer. Finally, chapter four reviews the conclusions drawn from each chapter and provides a summary of the thesis.

## 1.8 References

Abboud, J. A., & Soslowky, L. J. (2002). Interplay of the static and dynamic restraints in glenohumeral instability. *Clinical orthopaedics and related research*, (400), 48–57.

Anley, C., Chan, S.K.L., Snow, M. (2014). Arthroscopic treatment options for irreparable rotator cuff tears of the shoulder. *World Journal of Orthopedics*, 5, 557-565.

Burkart, A. C., Debski, R. E. (2002). Anatomy and function of the glenohumeral ligaments in anterior shoulder instability. *The Journal of Clinical Orthopaedics and Related Research*, (400), 32–9.

Burkhart, S.S., Lo, I.K. (2006). Arthroscopic rotator cuff repair. *The American Journal of Orthopedic Surgery*, 14(6):333-346.

Ellman, H., Hanker, G., Bayer, M. (1986). Repair of the rotator cuff. End-result study of factors influencing reconstruction. *The American Journal of Bone and Joint Surgery*, 68: 1136-1144.

Gerber, C., Fuchs, B., Hodler, J. (2000). The results of repair of massive tears of the rotator cuff. *The American Journal of Bone and Joint Surgery*, 82: 505-515.

Gerber, C., Wirth, S.H., Farshad, M. (2011). Treatment options for massive rotator cuff tears. *The Journal of Shoulder and Elbow Surgery*, 20: 20-29.

Hoppenfeld, S. (1976). Physical Examination of the Shoulder. *Physical Examination of the Spine & Extremities* (pp. 1–34). Upper Saddle River, NJ: Prentice Hall, Pearson Education.

Hurov, J. (2009). Anatomy and mechanics of the shoulder: review of current concepts. *Journal of hand therapy: official journal of the American Society of Hand Therapists*, 22(4), 328–42.

Ishihara, Y., Mihata, T., Tamboli, M., Nguyen, L., Park, K.J., McGarry, M.H., Takai, S., Lee, T.Q. (2014). Role of the superior shoulder capsule in passive stability of the glenohumeral joint. *The Journal of Shoulder and Elbow Surgery*, 23(5):642-648.

Mihata, T., McGarry, M.H., Pirolo, J.M., Kinoshita, M., Lee, T.Q. (2012). Superior capsule reconstruction to restore superior stability in irreparable rotator cuff tears: a biomechanical cadaveric study. *The American Journal of Sports Medicine*, 40: 2248-2255.

Mihata, T., Lee, T.Q., Watanabe, C., Fukunishi, K., Ohue, M., Tsujimura, T., Kinoshita, M. (2013). Clinical results of arthroscopic superior capsule reconstruction for irreparable rotator cuff tears. *The Journal of Arthroscopy and Related Surgery*, 29: 459-470.

Mihata, T., McGarry, M.H., Kahn, T., Goldberg, I., Neo, M., Lee, T.Q. (2016) Biomechanical role of capsular continuity in superior capsule reconstruction for irreparable tears of the supraspinatus tendon. *The American Journal of Sports Medicine*, DOI: 10.1177/0363546516631751.

Mihata, T., McGarry, M.H., Kahn, T., Goldberg, I., Neo, M., Lee, T.Q. (2016). Biomechanical effect of thickness and tension of fascia lata graft on glenohumeral stability for superior capsule reconstruction in irreparable supraspinatus tears. *Journal of Arthroscopy*, 32(3):418-426.

Moore, D.R., Cain, E.L., Schwartz, M.L., Clancy, W.G. (2006). Allograft reconstruction for massive, irreparable rotator cuff tears. *The American Journal of Sports Medicine*, 34: 392-396.

Pedowitz, R.A., Yamaguchi, K., Ahmad, C.S., Burks, R.T., Flatow, E.L., Green, A., Iannotti, J.P., Miller, B.S., Tashjian, R.Z., Watters, W.C., Wever, K., Turkelson, C.M., Qies, J.L., Anderson, S., St Andre, J., Boyer, K., Raymond, L., Sluka, P., McGowan, R. (2009). Optimizing the management of rotator cuff problems. *Journal of the American Academy of Orthopedic Surgery*, 19(6):368-379.

Plausinas, D., Jazrawi, L. M., Zuckerman, J. D., & Rockito, A. S. (2006). Anatomy and Biomechanics of the Shoulder. In A. A. Schepsis & B. D. Busconi (Eds.), *Sports Medicine* (p. 169). Pennsylvania, PA.

Savarese, E., Romeo, R. (2012). New solution for massive, irreparable rotator cuff tears: the subacromial “biodegradable spacer”. *Arthroscopic Techniques*, 1: 69-74.

Senekovic, V., Poberaj, B., Kovacic, L., Mikek, M., Adar, E., Dekel, A. (2013). Prospective clinical study of a novel biodegradable subacromial spacer in treatment of massive irreparable rotator cuff tears. *European Journal of Orthopedic Surgery and Traumatology*, 23: 311-316.

Senekovic, V., Poberaj, B., Kovacic, L., Mikek, M., Adar, E., Dekel, A. (2016). The biodegradable spacer as a novel treatment modality for massive rotator cuff tears: a prospective study with 5-year follow-up. *Archives of Orthopedic and Trauma Surgery*. DOI 10.1007/s00402-016-2603-9.

St. Pierre, P. Rotator cuff pathology. (2015) *ACSM's Sports Medicine: A Comprehensive Review*. Philadelphia: Wolters Kluwer Health, 317-322.

Swarm, D. L., Mahar, A. T., Weichel, D. W., & Pedowitz, R. A. (2007). Shoulder Anatomy and Biomechanics. In R. A. Pedowitz & D. H. Johnson (Eds.), *Practical Orthopaedic Sports Medicine & Arthroscopy* (145–156). Pennsylvania, PA: Lippincott Williams & Wilkins.

Terry, G. C., & Chopp, T. M. (2000). Functional Anatomy of the Shoulder. *Journal of Athletic Training*, 35(3), 248–255.

Tortora, G. J., & Grabowski, S. R. (2003). *Principles of Anatomy and Physiology*, Tenth Edition. (B. Roesch, Ed.) (10th ed., p. 1104). Hoboken, NJ: John Wiley & Sons, Inc.

Via A.G., De Cupis M., Spoliti M., Oliva F. (2013) Clinical and biological aspects of rotator cuff tears. *Muscles Ligaments Tendons Journal*. 3(2):70-9.

## Chapter 2

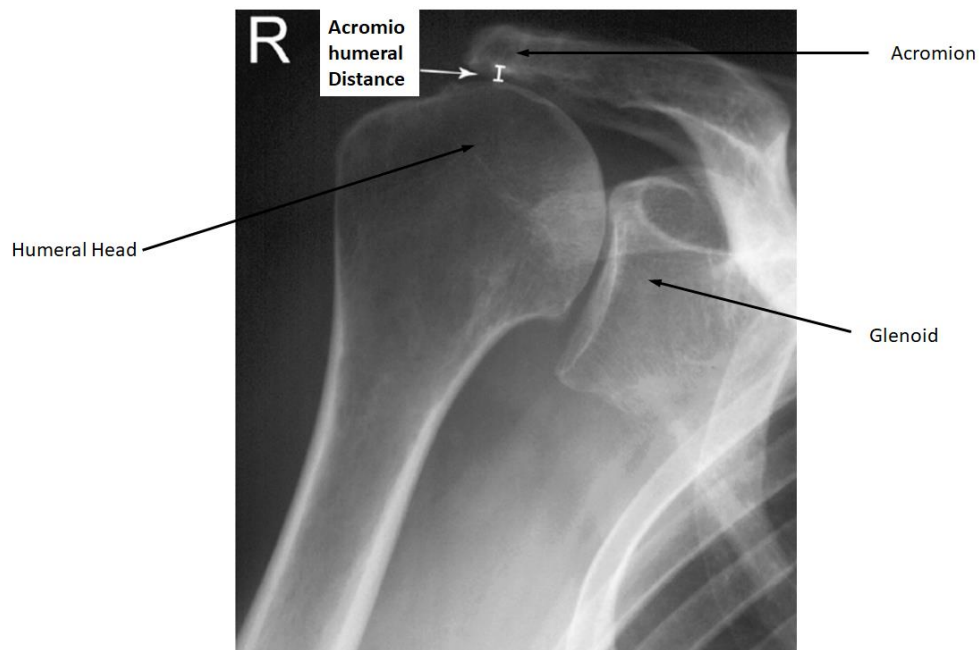
### A Comparison of Superior Capsular Reconstruction to the Subacromial Balloon Spacer

*This chapter directly compares the superior capsular reconstruction to the subacromial balloon spacer in the treatment of massive, irreparable rotator cuff tears. This biomechanical study examines the ability of both techniques to restore humeral head positioning and functional abduction forces.*

#### 2.1 Introduction

Massive, irreparable rotator cuff tears are large tears  $> 5$  cm with 2 or more rotator cuff tendons affected (Cofield, 2001). These large tears are extremely challenging to repair primarily due to tendon retraction, muscle atrophy and fatty infiltration (Melladao, 2005). The prognosis of massive, irreparable rotator cuff tears is difficult to predict. Patients usually complain of pain and reduced range of motion and this can have significant impact on quality of life.

In the setting of a massive, irreparable rotator cuff tear, there is a loss of the superior structural support of the glenohumeral joint, which results in superior humeral head migration. These tears can be described based on various radiographic measures including acromiohumeral distance, glenohumeral joint arthritis and degeneration of the acromion (Hamada, 1990). The acromiohumeral distance is a measure of superior humeral head migration and is measured from the undersurface of the acromion to the humeral head (See Figure 2-1). When the acromiohumeral distance is less than 7 mm, this is usually representative of a massive, irreparable rotator cuff tear in addition to the other factors mentioned previously including tendon retraction > 5 cm, fatty infiltration and muscle atrophy seen on MRI (Weiner,1970).



**Figure 2-1: Radiographic Depiction of the Acromiohumeral Distance**

*Radiograph of a right shoulder illustrating superior humeral head migration due to a massive, irreparable rotator cuff tear. The humeral head is not congruent in the glenoid fossa and is impinging on the undersurface of the acromion. As noted in the white box, the acromiohumeral distance is significantly narrowed.*



Surgical intervention is indicated in the setting of massive, irreparable rotator cuff tears to improve symptoms of pain and reduced range of motion when conservative treatment measures have failed and activities of daily living are inhibited. Unfortunately, treatment can be quite challenging and although multiple interventions have been introduced, there is no consensus on the gold standard treatment for an individual patient. There is a paucity of literature supporting any one surgical intervention, however, a reverse total shoulder arthroplasty has emerged as the preferred definitive treatment option in the older patient with significant glenohumeral arthritis and rotator cuff deficiency. Although a reverse total shoulder arthroplasty provides predictable pain relief and can offer improved range of motion and function (Mulieri 2010), there are significant risks associated with this surgery. In a systematic review performed by Petrillo, *et al.*, in 2017, there was a 17.4% complication rate associated with reverse total shoulder arthroplasty and a revision surgery rate of 7.3%. The complications included neurovascular injury, infection, periprosthetic fractures, component loosening or failure, joint dislocations and heterotopic ossification. The risk of complications, the longevity of the implants and the invasiveness of arthroplasty surgery have all brought into question the ideal treatment option for specific patients with massive, irreparable rotator cuff tears and no glenohumeral joint arthritis.

A surgical dilemma exists in the young patient, without evidence of glenohumeral joint arthritis in the setting of a massive, irreparable rotator cuff tear. Two new surgical techniques have been proposed in the treatment of massive, irreparable rotator cuff tears;

superior capsular reconstruction and the insertion of a subacromial balloon spacer. Currently there is limited evidence available promoting either technique but early, small clinical studies have shown promising results.

Mihata, *et al.*, in 2012 proposed superior capsular reconstruction for the treatment of massive, irreparable rotator cuff tears. The role of the superior capsule is to provide superior static stability to the glenohumeral joint. With a massive, irreparable postero-superior tear of the supraspinatus and infraspinatus tendon, there will be an inherent defect in the superior capsule. The goal of superior capsular reconstruction is to use a graft to prevent superior humeral head migration and regain joint alignment and motion. Mihata, *et al.*, have proposed this new technique and studied it biomechanically as well as clinically. In one of many biomechanical studies, Mihata, *et al.* proved that superior capsular reconstruction restored superior stability to the glenohumeral joint (Mihata, 2016). Clinically in 2013, Mihata, *et al.*, reported improved pain and range of motion, as well as improved acromiohumeral distance in a retrospective study of 24 patients that underwent arthroscopic superior capsular reconstruction at a mean 34 months post operatively.

The insertion of a subacromial balloon spacer was described initially in 2012. The goal of the balloon spacer is to reduce subacromial impingement and depress the humeral head to restore normal shoulder biomechanics. There have been no studies done that

examine the effect of the subacromial balloon spacer on shoulder kinematics. Furthermore, there have been no studies comparing the balloon to superior capsular reconstruction. Senekovic, *et al.*, published a prospective case series on 20 patients that underwent insertion of the subacromial balloon spacer and reported on three and five year follow up. These small studies have shown clinically significant improvements in shoulder function scores, improvements in range of motion and strength. Recently, Deranlot, *et al.*, in 2017, published a retrospective case series on 39 shoulders that underwent insertion of the subacromial balloon spacer and again reported significant improvement in shoulder function at the one year postoperative follow up mark.

Although both techniques have promising early clinical results, the studies are small sample sizes, with relatively short term follow up and are only level 4 evidence. The purpose of this study is to directly compare the biomechanics of the superior capsular reconstruction with that of the subacromial balloon spacer in the treatment of massive, irreparable rotator cuff tears. Specifically, superior humeral head migration and functional abduction force at varying degrees of static abduction angles will be compared. It was hypothesized that both superior capsular reconstruction and the subacromial balloon spacer will restore humeral head position to the native state at lower abduction angles, however, at higher shoulder abduction angles, it was hypothesized that the subacromial balloon spacer would better restore the humeral head position as compared to the superior capsular reconstruction. In terms of the functional abduction force, it was hypothesized that both

techniques would restore the force to the native state. The results from this study will yield important data on the biomechanics of both treatment options, as well as, help guide clinical practice of these two surgical procedures.


## 2.2 Materials and Methods

### 2.2.1 Cadaveric Specimen Preparation

Eight, previously frozen male cadaveric shoulders were used for this study (mean age 68, range 60-76 years). Pre-screening with CT scans was conducted to ensure no significant rotator cuff or glenohumeral joint pathology was present. Specimens were thawed at least 12 hours prior to testing. The overlying skin, soft tissues, muscles, capsule and joint were preserved. The four rotator cuff tendons were identified and tagged with heavy #5 non-absorbable braided suture (Ethibond, Ethicon, Johnson & Johnson, New Jersey, USA). The three heads of the deltoid muscle were exposed distally at the lateral aspect of the humeral shaft. The anterior, middle, and posterior heads of the deltoid were tagged through transosseous holes made in the distal humeral shaft with a 2.0 mm drill.

A load cell (ATI, Apex, NC) assembly unit was potted in to the humeral shaft using cement and the scapula was attached using a clamp and bolts to a shoulder simulator (Figure 2-2). A distal humerus restraining jig permitted static shoulder abduction in the scapular

plane (scaption) from 0° to 90°. The tagged rotator cuff muscles were attached to cables and routed to computer-controlled pneumatic actuators. These actuators controlled the loads placed on each muscle tendon unit. The deltoid was loaded at 40 and 80 N during testing and each individual rotator cuff muscle had a 10 N load applied (as per the protocol used by Mihata, *et al.* 2012 and 2016). Optical tracking sensors (Northern Digital, ON, Canada) were fixed to the scapula and humeral shaft to allow for the determination of bone and joint position.



**Figure 2-2: Shoulder Simulator Setup**

*The specimen is shown on the left side mounted in a clamp. Cables are sutured to the tendons of interest and routed to (computer-controlled) pneumatic (air) actuators shown on the right.*

## 2.2.2 Testing Protocol

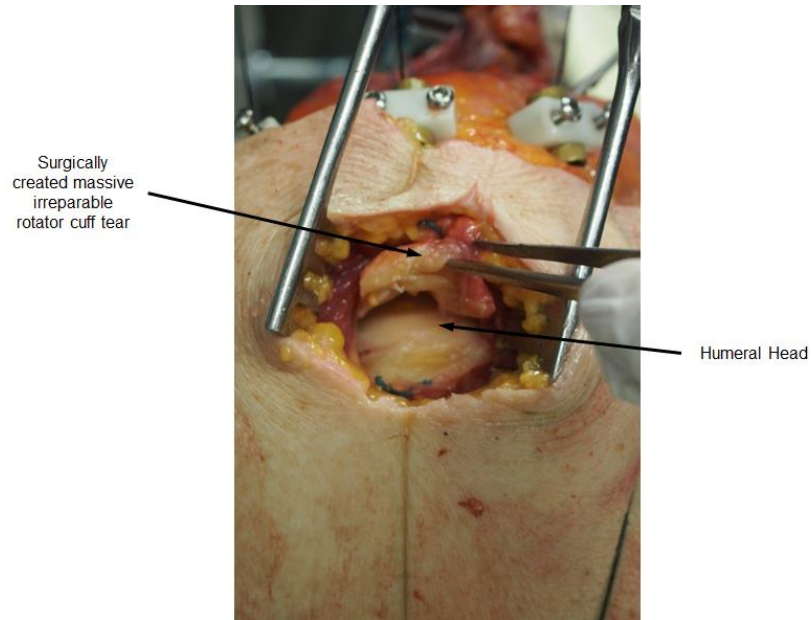
For each testing variable, superior humeral head migration and functional abduction forces were measured after the loads were applied at 0, 30, 60 and 90 degrees of static abduction in the scapular plane.

Four variables related to shoulder condition were sequentially tested as follows:

*Intact:* After the cadaveric specimen preparation and shoulder simulator mounting was completed, the intact shoulder state was initially tested. The intact shoulder was tested for superior humeral head migration and functional abduction force at 0, 30, 60 and 90 degrees of static abduction. This was achieved by locking the distal humerus restraining jig at the set angles and then applying the pneumatic loads as mentioned above. The optical tracking system and load cell measurements were taken 10 seconds following load application.

*Torn:* The second shoulder state tested was the massive, irreparable rotator cuff tear. Through a mini-open incision (direct lateral deltoid split), a massive, irreparable rotator cuff state was surgically created (Figure 2-3). Through this incision, the footprint (insertion of the supraspinatus and infraspinatus tendons) was visualized and accessed. A large, postero-superior full thickness tear involving both the supraspinatus and infraspinatus tendons was created. A 5 cm tear from anterior to posterior was created. The subscapularis and teres minor tendon were left intact. The superior capsule was removed with the

detached tendons. After the torn shoulder state was created, the mini deltoid split incision was closed with #5 ethibond sutures.



**Figure 2-3: Massive, Irreparable Rotator Cuff Tear State**

*The specimen is shown with a surgically created massive, irreparable rotator cuff tear of the right shoulder.*

*Balloon:* The third shoulder state tested was the subacromial balloon spacer. The mini deltoid split was re-opened and through the incision, the distance from the greater tuberosity to 1 cm medial to the superior glenoid rim was measured.


Based on this measurement of the subacromial space, the appropriate size balloon was selected as recommended in the InSpace Balloon technique manual (Table 2.1).

Subacromial Space Size	Balloon Size	Recommended Volume of Balloon (mL)
< 4 cm	Small	9-11
4-5 cm	Medium	14-16
> 5 cm	Large	23-25

**Table 2.1: Subacromial Balloon Sizing and Inflation Volumes**

All cadaveric specimens had a subacromial space larger than 5 cm and as such, a large balloon was used and inflated to 25 mL as per manufacturer's recommendations. The balloon was inserted using an introducing tube (Figure 2-4). The tube was placed 1 cm medial to the glenoid rim. The tube was pulled back and the balloon was inflated with saline using a syringe that was attached to the device handle. The balloon was then sealed and secured in place by sliding forward the button on the device handle. The delivery system was removed and again the deltoid split was closed using #5 ethibond suture. With the balloon inserted into the subacromial space, superior humeral head migration and functional abduction forces were measured at 0, 30, 60 and 90 degrees of static abduction.






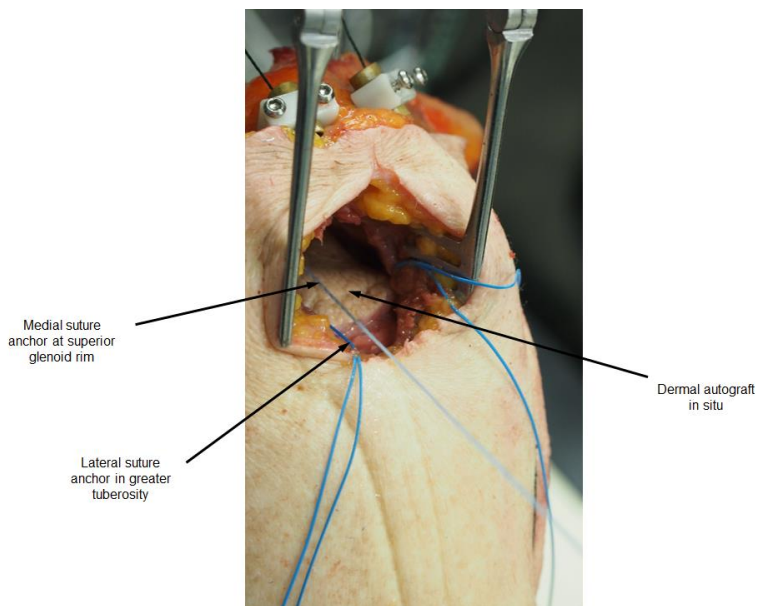
**Figure 2-4: Subacromial Balloon Spacer Insertion Device**

*Superior Capsular Reconstruction:* For the fourth cycle of testing, the balloon was deflated and removed through the mini deltoid split. The superior capsular reconstruction technique was subsequently performed through this same incision. A dermal autograft was selected and prepared at the time of the initial dissection. The graft thickness was measured with calipers. Two 2.8mm Q-FIX All-Suture Anchors (Smith & Nephew, London, UK) were inserted in to the superior glenoid bone. One anchor was placed at the superior most point on the glenoid corresponding to the 12 o'clock position. The second glenoid anchor was placed in the posterosuperior aspect of the glenoid rim corresponding to the upper edge of the remaining infraspinatus. Two 4.75mm Healicoil Suture Anchors (Smith & Nephew, London, UK) were placed in to the greater tuberosity, one at the anteromedial aspect of the exposed rotator cuff footprint and the other at the

posteromedial aspect of the footprint. The distance between all four anchors was measured to estimate the dimensions of the dermal autograft. Once measured, 5mm was added medially, posteriorly and anteriorly to the graft and 10mm was added laterally to cover the greater tuberosity. The sutures from the glenoid suture anchors were then passes through appropriate positions on the medial aspect of the dermal graft. The humerus was then placed in 30 degrees of scaption and the sutures from the medial row tuberosity anchors were then passed through the lateral aspect of the graft. The graft was tensioned taught at 30 degrees of humeral scaption. Once the medial row was secured, a suture-bridge type configuration was created with one suture from each anchor inserted in to two 5.5mm knotless suture anchors placed in the lateral aspect of the greater tuberosity. The posterior cuff – graft interval was sutured side-to-side with interrupted simple stitches. The deltoid split was reclosed using #5 Ethibond suture. Figure 2-5 shows the equipment and set up required to perform the superior capsular reconstruction and Figure 2-6 shows a cadaveric testing specimen after the superior capsular reconstruction has been performed in the lab.



**Figure 2-5: Superior Capsular Reconstruction Set Up**



**Figure 2-6: Superior Capsular Reconstruction in Cadaveric Specimen**

### 2.2.3 Outcome Variables

The main outcome variables of this study were superior humeral head position and functional abduction force.

Superior humeral head migration was monitored using the optical tracking system. The relative motion of the humeral head compared to the centre of the glenoid was measured. A reference coordinate system was developed for each specimen and the migration of the centre of the humeral head relative to the initial resting position of the humeral head in the glenoid was measured at various degrees of static abduction.

The functional abduction force was the abductive force at the mid humerus for a constant deltoid force. It was measured using a load cell positioned at a constant and fixed location at the distal humerus restraining jig. It was measured as an absolute change in the vertical component of force relative to the intact state. The functional abduction force was an indirect measure of abduction strength. This outcome variable was measured to assess the ability of each reconstruction to maximize shoulder muscle efficiency. It is a measure of the force exerted by the muscles to abduct the arm.

The outcomes were measured in each shoulder state; **intact, torn** (after creating a massive, irreparable rotator cuff tear), **balloon** (after inserting the subacromial balloon spacer), and **SCR** (superior capsular reconstruction).

#### 2.2.4 Statistical Analysis

Repeated measures of analysis of variance was used for statistical analysis. Bonferonni correction was used to account for the multiple comparisons made. Statistical significance was defined as  $p < 0.05$ . The abduction angle, deltoid load and shoulder state were the independent variables with humeral head migration and functional abduction force being the dependent variable.

## 2.3 Results

### 2.3.1 Humeral Head Migration

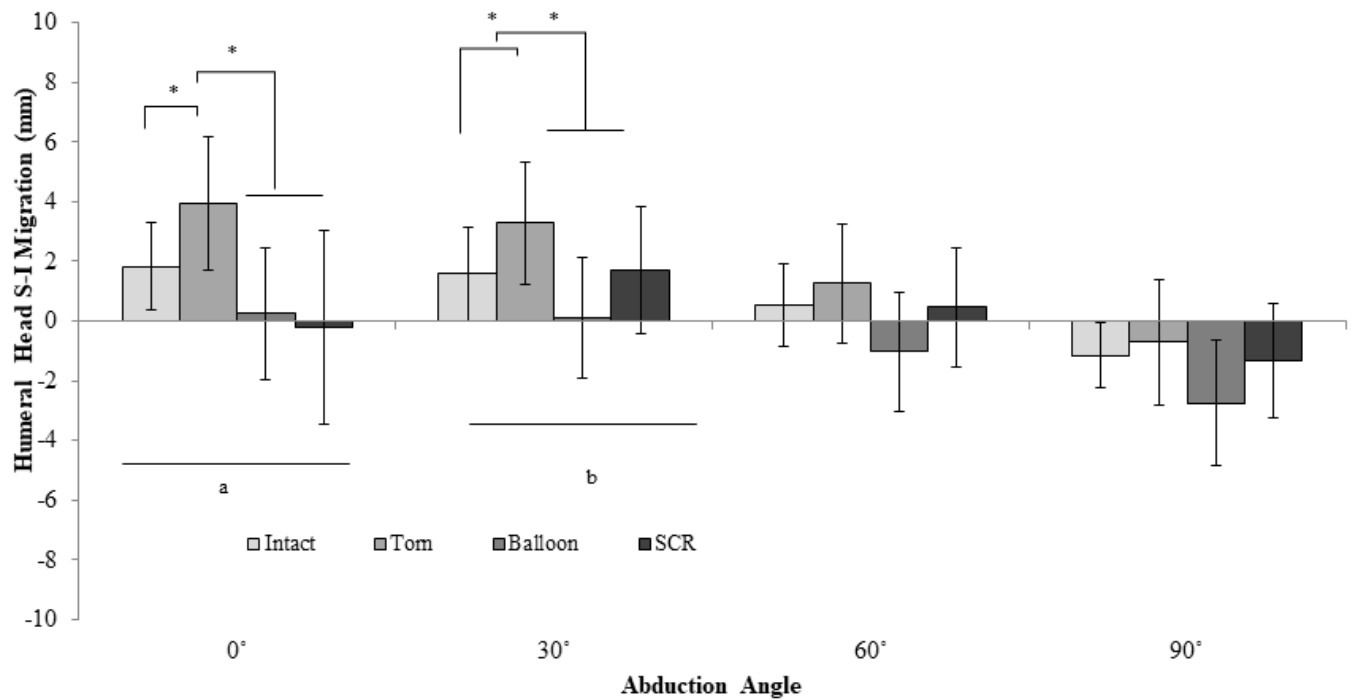
Figure 2-7 shows the results of humeral head migration for each shoulder state at varying degrees of shoulder abduction when the deltoid was loaded at 80 N. When the deltoid muscle load was increased from 40 to 80 N, the humeral head translated superiorly an average of  $1.5\pm 0.3$  mm ( $p<0.001$ ) for all parameters tested.

After creating a massive, irreparable rotator cuff tear, the humeral head migrated superiorly  $3.5\pm 0.7$  mm ( $p=0.028$ ) at  $0^\circ$  of abduction and  $2.9\pm 0.6$  mm ( $p=0.017$ ) at  $30^\circ$  of abduction when 80 N was applied to the deltoid muscle. At  $60^\circ$  and  $90^\circ$  of abduction, there was no significant difference in humeral head position ( $p=0.138$  and  $p=0.764$ , respectively) as compared to the intact state. After insertion of the subacromial balloon spacer, the humeral head was translated inferiorly by  $2.8\pm 1.9$  mm ( $p=0.006$ ) relative to the torn state. The superior capsular reconstruction also resulted in inferior humeral head translation of  $1.8\pm 1.6$  mm ( $p=0.031$ ) as compared to the torn state. Therefore, both techniques restored humeral head position after a massive, irreparable rotator cuff tear and this was statistically significant at all abduction angles.

When comparing the humeral head position between the intact state and after insertion of the subacromial balloon spacer, there were no significant differences detected in any position of shoulder abduction ( $p=0.177$ ). Furthermore, there were no significant differences in humeral head position between the intact state and the superior capsular reconstruction in any position of shoulder abduction ( $p=1.00$ ). When directly comparing the balloon state with the superior capsular reconstruction state, there were no significant differences in humeral head position between the two techniques ( $p=1.00$ ).

#### 2.3.1.1 The Effect of Abduction Angle on Humeral Head Migration

Overall, each abduction angle state ( $0^\circ, 30^\circ, 60^\circ$  and  $90^\circ$ ) had a significant effect on humeral head migration ( $p<0.001$ ). As shoulder abduction increased, the humeral head centre was translated inferiorly for all shoulders states (intact, torn, balloon and superior capsular reconstruction).



**Figure 2-7: Results of Humeral Head Migration at Varying Abduction Angles at 80N of Deltoid Load**

The mean  $\pm$  1 SD of the humeral head migration for the various shoulder states (intact, torn, balloon and SCR) and shoulder abduction angles (0,30,60 and 90°) are shown in Figure 2-7. A positive value on the Y axis represents superior humeral head migration, where as a negative value on the Y axis represents inferior humeral head migration relative to intact state. An asterisk is marked over statistically significant results. The average results of humeral head migration at each abduction angle is illustrated above. “a” indicates statistical significance between 0° and 90° ( $p= 0.015$ ) and “b” indicates statistical significance between 30°, 60° and 90° ( $p < 0.003$ ).



### 2.3.1.2 The Effect of Shoulder State on Humeral Head Migration

The shoulder state resulted in a statistically significant effect on humeral head migration ( $p < 0.001$ ). Inducing a massive, irreparable rotator cuff tear caused the humeral head to migrate  $1.3 \pm 0.9$  mm superiorly ( $p = 0.015$ ) relative to the intact state when considering all abduction angles and deltoid loads together. Additionally, both the balloon and superior capsular reconstruction moved the humeral head inferiorly by  $2.8 \pm 1.9$  mm ( $p = 0.006$ ) and  $1.8 \pm 1.6$  mm ( $p = 0.031$ ) relative to the torn state, respectively.

### 2.3.1.3 The Effect of Deltoid Load on Humeral Head Migration

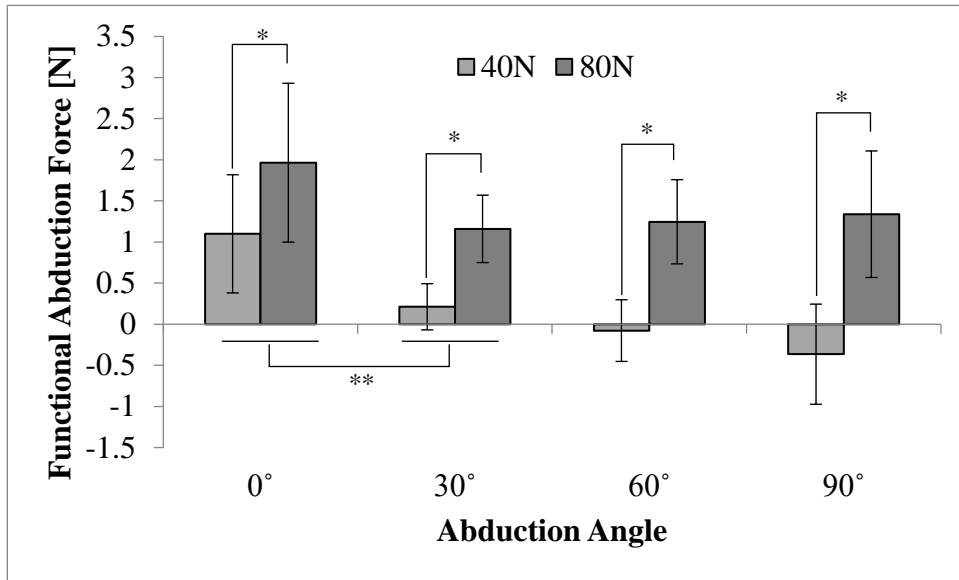
As mentioned above, the deltoid muscle load had a significant effect on humeral head migration ( $p < 0.001$ ). When increasing the deltoid force from 40 to 80 N, the humeral head migrated superiorly on average  $0.9 \pm 0.2$  mm ( $p < 0.001$ ), for all shoulder states investigated. Thus, the results for humeral head migration are shown when the deltoid is activated at 80 N. The effect of this increased deltoid load on superior humeral head migration was significantly decreased as the abduction angle increased ( $p = 0.002$ ). In summary, as the abduction angle of the arm increases, the superior directed force from the deltoid muscle on humeral head migration is attenuated.

## 2.3.2 Functional Abduction Force

The functional abduction force was measured as an indirect measure of abduction strength. Clinically, resisted abduction is measured on physical examination to assess strength of the rotator cuff muscles and the deltoid muscle. The functional abduction force measured in this study is the additional force needed by the muscles to abduct the arm after accounting for the weight of the arm at a fixed distance on the humeral shaft. It is an absolute change in the vertical component of force measured in Newtons relative to the intact state.

### 2.3.2.1 The Effect of Abduction Angle on Functional Abduction Force

Abduction angle ( $0^\circ$ ,  $30^\circ$ ,  $60^\circ$  and  $90^\circ$ ) had a significant effect on functional humeral abduction force ( $p=0.026$ ) (Figure 2-8). In addition, abduction angle interacted significantly with deltoid load ( $p=0.001$ ), such that abduction angle only significantly affected functional humeral abduction force at 40N of deltoid load. As the abduction angle increased, the functional humeral abduction force decreased with a constant load of 40N applied to the deltoid muscle. When increasing the abduction angle from  $0^\circ$  to  $60^\circ$ , the functional humeral abduction force significantly decreased by  $1.2\pm 0.8\text{N}$  ( $p=0.013$ ). When increasing the abduction angle from  $0^\circ$  to  $90^\circ$ , the functional humeral abduction force significantly decreased by  $1.5\pm 0.9\text{N}$  ( $p=0.024$ ).

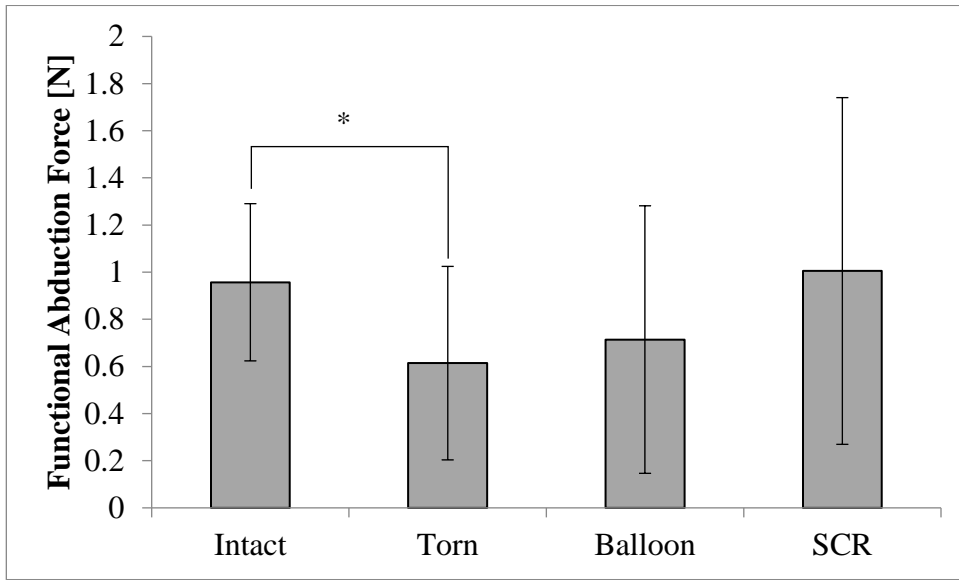


**Figure 2-8: The Effect of Abduction Angle on Functional Abduction Force**

The mean  $\pm$  1 SD of the functional abduction force for the various shoulder abduction angles (0,30,60 and 90°) for both deltoid loads (40 and 80 N) are shown in Figure 2-8 when considering all shoulder states together. The asterisks mark the statistically significant values.

### 2.3.2.2 The Effect of Shoulder State on Functional Abduction Force

Figure 2-9 shows the results of the effect of shoulder state on functional abduction force when considering all abduction angles and both deltoid loads together. When comparing the intact shoulder to the torn shoulder state, the functional abduction force was significantly lower for the torn state ( $1.2 \pm 0.7N$ ,  $p = 0.009$ ). There was no statistically significant difference detected between the intact state and either the balloon augment ( $p = 0.403$ ) or the superior capsular reconstruction ( $p = 1.000$ ) for the functional abduction force.



**Figure 2-9: The Effect of Shoulder State on Functional Abduction Force**

*The mean  $\pm$  1 SD of the functional abduction force for the various shoulder states (intact, torn, balloon and SCR) are shown in Figure 2-9. This graph demonstrates the various shoulder states on the X axis (SCR = superior capsular reconstruction) against the functional abduction force on the Y axis. The asterisk marks the statistically significant difference.*

### 2.3.2.3 The Effect of Deltoid Load on Functional Abduction Force

When the deltoid muscle load was increased from 40 to 80 N, considering all abduction angles and shoulder states together, the functional abduction force on average was increased by  $1.2 \pm 0.2$  N. The deltoid muscle load had a statistically significant effect on functional abduction force ( $p < 0.001$ ).

## 2.4 Discussion

In this study, the subacromial balloon spacer was compared to the superior capsular reconstruction technique for the treatment of massive, irreparable rotator cuff tears. Static abduction was tested in a fixed arc and the primary outcomes evaluated were humeral head migration and functional abduction force. To re-iterate, the three independent variables evaluated were shoulder state, abduction angle, and deltoid load.

### 2.4.1 Shoulder State

There were four different shoulder states evaluated; **intact** shoulder, **torn** (massive, irreparable rotator cuff tear), **balloon** (subacromial balloon spacer) and **SCR** (superior capsular reconstruction). There were no statistically significant differences in humeral head positioning between the subacromial balloon spacer ( $p=0.177$ ), the superior capsular reconstruction ( $p=1.000$ ) and the intact shoulder. Both techniques were able to restore humeral head position as compared to the intact shoulder. After creating a tear, the humeral head position was significantly affected ( $p=0.015$ ) and both the subacromial balloon spacer ( $p=0.006$ ) and the superior capsular reconstruction ( $p=0.031$ ) were able to significantly lower the humeral head. This was true when considering all abduction angles and deltoid loads. After a massive, irreparable rotator cuff tear, the humeral head migrates superiorly and both techniques were able to restore the humeral head in the glenoid fossa. Overall, both techniques effectively depressed the humeral head, one using a balloon spacer to

physically depress the humeral head and the other, reconstructing the superior capsule of the joint, which prevented the humeral head from migrating upwards. Once the surgical tear was created, there was a loss in the superior support of the rotator cuff musculature allowing for superior humeral head migration with deltoid muscle activation and during abduction. In addition, there was no significant difference between superior capsular reconstruction and the subacromial balloon spacer in their ability to restore humeral head position ( $p=1.000$ ). Both techniques were effective in restoring humeral head position after a massive, irreparable rotator cuff tear. The balloon spacer fills the subacromial space and thus prevents superior humeral head migration after a tear. At lower abduction angles, the superior capsular reconstruction graft is well tensioned and prevents superior humeral head migration. At higher abduction angles, although the graft was likely not tensioned, the resultant force vector on the humeral head does not create a superior directed force. This may explain why even at higher abduction angles the SCR technique was comparable to the balloon spacer.

The functional abduction force was an indirect measure of abduction strength and when comparing the intact shoulder to the torn state, there was a significant decrease in the functional abduction force in the torn state ( $p=0.009$ ). After a massive, irreparable rotator cuff tear, the abduction strength would be reduced and this was demonstrated by a reduction in the functional abduction force. This makes sense in the setting of a massive, irreparable muscle tear, the arm cannot generate as much force to abduct the arm as compared to the

intact state. The weakened muscle is from the injury or in this case the surgically created massive, irreparable rotator cuff tear. The superior capsular reconstruction and the subacromial balloon spacer were both able to restore functional abduction force to the intact state. There was no significant difference between the intact, the balloon spacer ( $p=0.403$ ) or the superior capsular reconstruction ( $p=1.000$ ) state in terms of functional abduction force. This indicates that both techniques were able to restore abduction strength in the cadaveric models. Although after creating a massive superior deficit in the rotator cuff muscles, by restoring the humeral head position, both techniques also restored abduction strength. Since the glenohumeral joint positioning is restored to the intact state, the muscle forces working at the joint would be restored to their baseline function and work equally to abduct the arm. The weakness created by the massive, irreparable rotator cuff tear was likely offset by the balloon and superior capsular reconstruction restoring the humeral head position.

#### 2.4.2 Abduction Angle

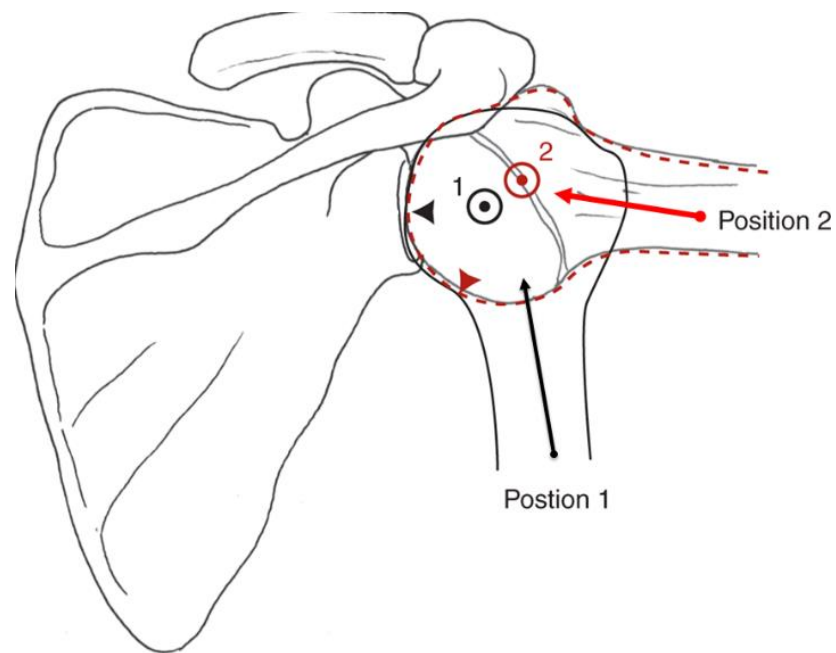
Static shoulder abduction was measured at  $0^\circ$ ,  $30^\circ$ ,  $60^\circ$  and  $90^\circ$ . When pooling all the shoulder states and deltoid loads together, each abduction angle had a significant effect on humeral head migration ( $p<0.001$ ). For all shoulder states, the humeral head was translated inferiorly as the abduction angle increased. When considering all shoulder states (torn, intact, subacromial balloon spacer and superior capsular reconstruction), there was a

significant difference in humeral head migration at 0° and 90° of shoulder abduction ( $p=0.015$ ). Additionally, there was a significant difference in humeral head migration between 30°, 60° and 90° of shoulder abduction ( $p<0.003$ ). At 0° and 30° of shoulder abduction, there was a significant difference in humeral head migration between the intact and torn state and the torn and the two treatment states. At higher abduction angles (60° and 90°), the difference in humeral head position was attenuated and this may be explained by the fact that at higher abduction angles, the resultant force vector of the deltoid muscle is such that superior humeral head migration would be minimal and thus differences between humeral head migration in different shoulder states would be more difficult to detect.

The abduction angles had a significant effect on functional abduction force ( $p=0.026$ ) when considering all shoulder states and deltoid loads. When the deltoid was loaded at 40 N, the abduction angle had a significant effect on functional abduction force ( $p=0.001$ ), however at 80 N this effect was not seen. This may be explained by the fact that at 80 N load on the deltoid, no additional muscle force was needed to abduct the arm and thus no difference was detected between abduction angles. When increasing the abduction angle, the functional abduction force decreased, in all shoulder states with the deltoid muscle loaded at 40 N. Clinically this would suggest that at higher abduction angles, the resisted abduction strength is decreased. This may be explained by the fact that at higher abduction angles, the arm is farther away from the body and an increased force is



required to achieve the same resistance than when the arm is adducted to the body. This can be linked back to the resultant deltoid force vectors acting on the shoulder when the arm is adducted as compared to abducted at  $90^\circ$  (see Figure 2-10).



**Figure 2-10 Resultant Vector of Deltoid Muscle Forces**

This figure illustrates the resultant vector of the deltoid muscle forces when the shoulder is in position 1 (adduction/ $0^\circ$  of abduction) and position 2 ( $90^\circ$  of abduction).

### 2.4.3 Deltoid Load

The deltoid muscle was fired at 40 and 80 N during the testing cycles and when the load was increased from 40 to 80 N, the humeral head migrated superiorly. This was statistically significant for all parameters including at all abduction angles and in all shoulder states ( $p < 0.001$ ). The deltoid muscle is a large muscle and when contracted its primary role is shoulder abduction. In the setting of a massive, irreparable rotator cuff tear, there is a lack of superior stability to the glenohumeral joint with the supraspinatus tendon, the upper part of the infraspinatus tendon and the superior capsule being torn. Superior humeral head migration is caused by a deficiency in the superior stability of the joint. This was demonstrated in the torn shoulder state when the deltoid muscle was fired at 80 N and the humeral head migrated superiorly an average of  $3.5 \pm 0.7$  mm ( $p = 0.028$ ) at  $0^\circ$  of abduction and  $2.9 \pm 0.6$  mm ( $p = 0.017$ ) at  $30^\circ$  of abduction. At higher abduction angles, the effect of increased deltoid load (80 N) on superior humeral head migration was significantly decreased ( $p = 0.002$ ). This may be explained by the fact that at higher abduction angles, the superiorly directed force vector of the deltoid muscle is decreased, resulting in less superior humeral head migration and more of an axial loading joint compression force (see Figure 2-10 above).

When the deltoid muscle load was increased from 40 to 80 N, the functional abduction force was significantly increased ( $p < 0.001$ ) for all shoulder states and at all

abduction angles. This is intuitive as the deltoid muscle contributes significantly to abduction strength and when the load is increased the functional abduction force will also increase.

Our initial hypothesis was partly accepted; both the superior capsular reconstruction and the subacromial balloon spacer restored humeral head position to the native state. However, this was held true at all abduction angles. The hypothesis stated that at higher abduction angles the subacromial balloon spacer would be more effective in restoring humeral head position as compared to the superior capsular reconstruction. The rationale behind this hypothesis was that the graft used in the superior capsular reconstruction is a non contractile graft and although it is tensioned at 30 degrees, at higher abduction angles it would fold, similar to an accordion and lose its ability to provide superior stability as compared to the balloon. This in fact was not correct because as the abduction angle increased, the direction of the deltoid muscle force did not result in superior humeral head migration. There was an overall less superior directed force from the deltoid muscle resulting in reduced superior humeral head migration at higher abduction angles and thus no difference was found between both techniques at higher abduction angles. This may indicate that the important aspect of abduction in the massive rotator cuff tear state is humeral head depression during the initiation of the motion (below 30 degrees), which both techniques were able to accomplish.

#### 2.4.4 Strengths & Limitations

This is the first study to examine the biomechanics of the subacromial balloon spacer and directly compare it to the superior capsular reconstruction. The surgical challenges of managing massive, irreparable rotator cuff tears is an exciting and rapidly advancing topic for shoulder surgeons. There is limited evidence available supporting these two new surgical techniques and this study substantially adds to the current body of literature and encourages additional comparative clinical studies.

Although the data collected from this study is important and will help guide the future management of massive, irreparable rotator cuff tears, there are some limitations to the study. Only one plane of motion was tested at time zero. Furthermore, shoulder abduction was static motion in a closed circuit. This does not represent a human dynamic model; however, cadaveric studies are necessary to yield important background information before applying the treatments clinically. Our outcomes of humeral head migration as a surrogate for subacromial impingement, and functional abduction force representing abduction strength, have no proven clinical correlation. The assumption is that clinical scores would improve with restoration of humeral head position and strength, however, further studies are needed to evaluate for clinical symptoms such as pain relief and improvement in daily function.

Additionally, a potential weakness was the lack of randomization for the shoulder states tested. In the initial pilot test and protocol, the goal was to randomize the shoulder states in specimens. However, in conducting the superior capsular reconstruction and then the balloon, the cadaver specimen sustained damage during take down of the superior capsular reconstruction. As such, the protocol was conducted with the reconstructions in series.

Finally, the error bars are quite large for the results. This can be explained by the inter-specimen variability and the small number of specimens tested. This is to be expected with cadaveric specimen testing. In addition, the pooling of the data to a single comparison and combining all variations across all tests leads to larger error bars.

In this study, both superior capsular reconstruction and the subacromial balloon spacer proved effective at restoring humeral head position and strength after a massive, irreparable rotator cuff tear during shoulder abduction. Based on this study, both techniques could be considered as similar alternatives in the treatment for massive, irreparable rotator cuff tears. Further studies need to examine the long-term effectiveness of both techniques.

## 2.5 Conclusions

This is the first study to directly compare superior capsular reconstruction with the subacromial balloon spacer. Native humeral head position was effectively restored with both techniques. After creating a massive, irreparable rotator cuff tear, the humeral head position was significantly affected but adequately restored to the native state with both the superior capsular reconstruction and the subacromial balloon spacers at all abduction angles.

At higher abduction angles, the superiorly directed force vector on the humeral head is decreased and the role of the deltoid muscle in inducing superior humeral head migration is decreased. There were no significant differences between the functional abduction force when comparing the intact state to the balloon augment or superior capsular reconstruction state. In other words, there is no extra force applied by the rotator cuff muscles to abduct the arm with either treatment option and abduction strength was restored.

Based on this biomechanical study, both superior capsular reconstruction and the subacromial balloon spacer function well to prevent superior humeral head migration and restore normal glenohumeral joint position and forces during various abduction states as compared to the intact shoulder state. Further investigations are needed to determine if these results are sustained over time in a dynamic model.

## 2.6 References

Ackland, D.C. (2010) Moment arms of the shoulder musculature after reverse total shoulder arthroplasty. . *The Journal of Bone and Joint Surgery*, 92(5):1221–1230.

Bedi, A., Dines, J., Warren, R.F., Dines, D.M. (2010). Massive tears of the rotator cuff. *The Journal of Bone and Joint Surgery*, 92:1894-908.

Cofield, R.H., Parvizi, J., Hoffmeyer, P.J., Lanzer, W.L., Ilstrup, D.M., Rowland, C.M. (2001). Surgical repair of chronic rotator cuff tears. A prospective long-term study. *The Journal of Bone and Joint Surgery*, 83:71-7.

Deranlot, J., Herisson, O., Nourissat, G., Zbili, D., Werthel, J. D., Vigan, M., & Bruchou, F. (2017). Arthroscopic Subacromial Spacer Implantation in Patients With Massive Irreparable Rotator Cuff Tears: Clinical and Radiographic Results of 39 Retrospectives Cases. *Arthroscopy: The Journal of Arthroscopic and Related Surgery*. <https://doi.org/10.1016/j.arthro.2017.03.029>.

Hamada, K., Fukuda, H., Mikasa, M., Kobayashi, Y. (1190). Roentgenographic findings in massive rotator cuff tears: A long-term observation. *Clinical Orthopedics and Related Research*, 254:92-6.

Mihata, T., McGarry, M.H., Pirolo, J.M., Kinoshita, M., Lee, T.Q. (2012). Superior capsule reconstruction to restore superior stability in irreparable rotator cuff tears: a biomechanical cadaveric study. *The American Journal of Sports Medicine*, 40: 2248-2255.

Mihata, T., Lee, T.Q., Watanabe, C., Fukunishi, K., Ohue, M., Tsujimura, T., Kinoshita, M. (2013). Clinical results of arthroscopic superior capsule reconstruction for irreparable rotator cuff tears. *The Journal of Arthroscopy and Related Surgery*, 29: 459-470.

Mihata, T., McGarry, M.H., Kahn, T., Goldberg, I., Neo, M., Lee, T.Q. (2016) Biomechanical role of capsular continuity in superior capsule reconstruction for irreparable tears of the supraspinatus tendon. *The American Journal of Sports Medicine*, DOI: 10.1177/0363546516631751.

Mihata, T., McGarry, M.H., Kahn, T., Goldberg, I., Neo, M., Lee, T.Q. (2016). Biomechanical effect of thickness and tension of fascia lata graft on glenohumeral stability for superior capsule reconstruction in irreparable supraspinatus tears. *Journal of Arthroscopy*, 32(3):418-426.



Mellado, J.M., Calmet, J., Olona, M., Esteve, C., Camins, A., Perez Del Palomar, L. (2005). Surgically repaired massive rotator cuff tears: MRI of tendon integrity, muscle fatty degeneration, and muscle atrophy correlated with intraoperative and clinical findings. *The American Journal of Roentgenology*, 184:1456-63.

Mulieri, P., Dunning, P., Klein, S., Pupello, D., Frankle, M. (2010). Reverse shoulder arthroplasty for the treatment of irreparable rotator cuff tear without glenohumeral arthritis. *The Journal of Bone and Joint Surgery*, 92:2544-56.

Petrillo, S., Longo, U. G., Papalia, R., & Denaro, V. (2017). Reverse shoulder arthroplasty for massive irreparable rotator cuff tears and cuff tear arthropathy: a systematic review. *The Journal of Musculoskeletal Surgery*. <https://doi.org/10.1007/s12306-017-0474-z>.

Savarese E, Romeo R. (2012). New solution for massive, irreparable rotator cuff tears: The subacromial “biodegradable spacer”. *The Journal of Arthroscopy Techniques*,1:69-74.

Sevivas, N., Ferreira, N., Andrade, R., Moreira, P., Portugal, R., Alves, D., Espregueira-Mendes, J. (2017). Reverse shoulder arthroplasty for irreparable massive rotator cuff tears: a systematic review with meta-analysis and meta-regression. <https://doi.org/10.1016/j.jse.2017.03.039>.

Weiner, D.S., Macnab, I. (1970). Superior migration of the humeral head. A radiological aid in the diagnosis of tears of the rotator cuff. *The Journal of Bone and Joint Surgery*, 52:524-7.

## Chapter 3

### A Biomechanical Study of the Subacromial Balloon Spacer in the Treatment of Massive, Irreparable Rotator Cuff Tears

*This chapter reviews the subacromial balloon spacer technique in the treatment of massive, irreparable rotator cuff tears. Similar concepts to Chapter 2 will be reviewed in the introduction section. The methodology for this study is also similar to Chapter 2. This is the first biomechanical study examining the subacromial balloon spacer in its ability to function as a device to depress the humeral head in the setting of massive, irreparable rotator cuff tears.*

#### 3.1 Introduction

As documented in the previous two chapters, massive, irreparable rotator cuff tears are defined by tears greater than 5 cm in size, with 2 or more tendons involved, with tendon retraction and chronic changes such as muscle atrophy and fatty infiltration, and which cannot be repaired directly back to the greater tuberosity of the humerus (Gerber, 2011). The current management of these tears is challenging as no individual surgical technique has demonstrated clinical superiority in the literature. A surgical dilemma exists in the case of a younger patient with a massive, irreparable rotator cuff tear and no evidence of

glenohumeral joint arthritis. Various treatment options exist including but not limited to; subacromial decompression and biceps tenotomy, partial tendon repairs, and interposition of synthetic grafts, however, no definitive guidelines for optimal surgical treatment has been accepted. Newer arthroscopic treatments have been proposed in the treatment algorithm of massive, irreparable rotator cuff tears that are deemed less invasive and perhaps an interim procedure, prolonging the time to a more definitive procedure such as arthroplasty.

The subacromial balloon spacer technique (as studied in Chapter 2) was first published by Savarese, *et al.*, in 2012 and then by Gervasi, *et al.*, in 2014 as a new arthroscopic treatment option in the management of massive, irreparable rotator cuff tears. This surgical technique involves the insertion of a biodegradable subacromial balloon shaped spacer between the humeral head and the acromion. The goal of the treatment is to depress the humeral head, prevent subacromial impingement and restore normal shoulder biomechanics. The technique was described arthroscopically and could be performed in outpatient setting under local anesthesia. This novel treatment may be useful for high risk surgical candidates or as an interim surgical procedure prior to considering arthroplasty.

Currently the main contraindications to implantation of the subacromial balloon spacer includes allergies to the device material or active shoulder joint infection. Possible risks of the device implantation include local irritation from the balloon including a foreign body reaction, infection, inflammation and tissue necrosis (Savarese, 2012). No clinical safety studies have been done specifically looking at the subacromial balloon spacer. The balloon spacer is made of poly-L-lactide-co- $\epsilon$ -caprolactone, which is a biodegradable material. Ramot, *et al.*, in 2015, published an animal study testing the long term local and systemic safety of poly-L-lactide-co- $\epsilon$ -caprolactone after intraarticular implantation in rats. Overall, the results of this study showed positive outcomes for both local and systemic tolerability of the material with no inherent toxic or tumorigenic properties.

Senekovic, *et al.*, in 2012, published the first prospective clinical trial after inserting 20 subacromial balloon spacers in patients with massive, irreparable rotator cuff tears. There were 11 males and 9 females included in this study, with the average age of 70.5 years. A significant improvement in patient symptoms were noted as early as 1 week and at 3 years post operatively, there was sustained improvement in subjective pain, shoulder function and strength as assessed by the Constant score. Additionally, there were no adverse events related to the device insertion or during follow up. This first human study demonstrated clinical safety and efficacy in a small group of patients with massive, irreparable rotator cuff tears. A five-year follow up study on the same cohort of patients reported sustained clinical improvements (Senekovic, 2016). The device was deemed to

be a viable alternative treatment option that was low risk, minimally invasive and effective. Deranlot, *et al.*, in 2017 published a retrospective review of 37 patients after arthroscopic insertion of the subacromial balloon spacer. The mean age of patients in this study was 69.8 years and on an average follow up of 1 year, all patients had a significant increase in their post operative range of motion and mean Constant score. Radiographically, there was a significant improvement in the acromiohumeral distance after implantation of the device. There was only one adverse patient event of balloon spacer migration, and the patient underwent a revision implantation of the device. This study adds to the existing evidence that the subacromial balloon spacer has had early positive clinical results.

In addition, clinical studies using the spacer as an adjunct to protect primary rotator cuff tears have been done. The success rate of primary rotator cuff repairs is inversely proportional to the tear size, with larger tears having a higher failure rate post operatively (Szollosy, 2014). In 2014, Szollosy, *et al.*, proposed using the subacromial balloon spacer to protect rotator cuff repairs by placing the spacer between the acromion and repaired rotator cuff tendon. The theory was that the balloon spacer would maintain humeral head position and reduce impingement between the repair and the acromion. The limitation to the use of the spacer was that overstuffing the subacromial space may lead to extrinsic compression of the repair site or cause excessive humeral head depression. The optimal fill volume and balloon sizing would be important to prevent this.

Although there have been some clinical studies published on the insertion of the subacromial balloon spacer, no biomechanical studies have tested the ability of the device to depress the humeral head. The objective of this study was to evaluate the balloon as a device to depress the humeral head and compare the balloon to the intact shoulder and after a massive, irreparable rotator cuff tear. This study will examine the impact of balloon volume on humeral head migration to help understand the optimal use of the subacromial balloon spacer as a device. Humeral head migration in various degrees of shoulder abduction and the various fill volumes of the balloon will be tested. This data is important to understand how the subacromial balloon spacer works as a device and will add to the current literature on this novel treatment.

## 3.2 Materials and Methods

### 3.2.1 Cadaveric Specimen Preparation

Cadaveric preparation was described in Chapter 2 and the shoulder simulator set up was demonstrated in Figure 2-2. Eight, right, previously frozen male cadaveric shoulders were used for testing. Each specimen had a CT scan of the shoulder that was reviewed to ensure there was no rotator cuff or bony pathology. The specimens were defrosted a minimum of 12 hours prior to testing. The first step in the cadaveric preparation was soft tissue dissection. The dissection involved identifying and tagging the four rotator cuff tendons with a #5 Ethibond suture. The joint capsule, deltoid muscle and overlying skin

were left intact. The deltoid muscle was tagged through transosseous bone tunnels made in the distal humeral shaft using a 2.0 mm drill. The three heads of the deltoid muscle were individually secured. The humeral shaft was potted using cement and the scapula was attached using bolts and mounted on the shoulder simulator (Figure 3-1). Each of the rotator cuff muscles, as well as the deltoid muscle, were attached to cables that were routed to pneumatic actuators. The computer controlled actuators placed 10 N of load on each rotator cuff muscle and 40 and 80 N of load on the deltoid muscle during testing cycles. The optical tracker sensors were attached to the scapula and humeral shaft.

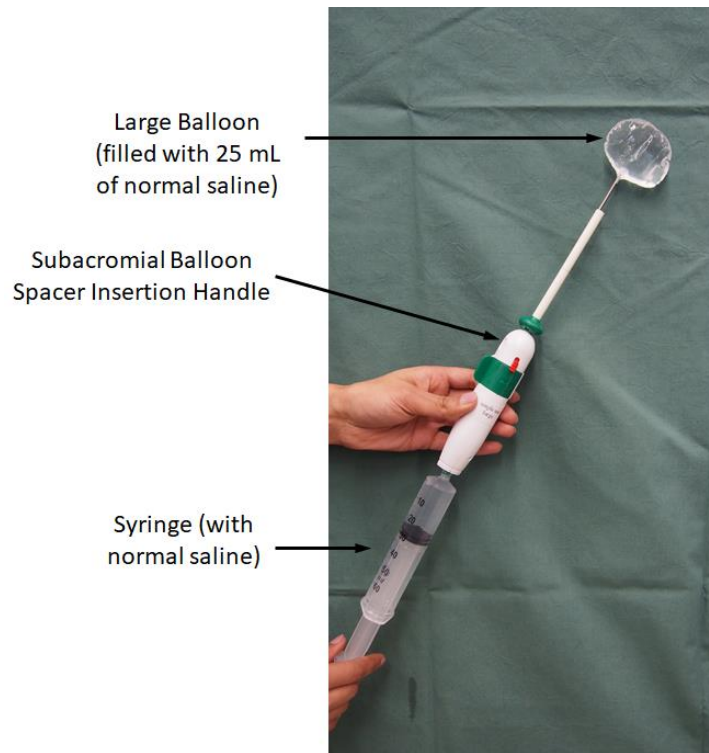
### 3.2.2 Testing Protocol

After the soft tissue dissection and specimen preparation was completed, the cadaveric shoulder was mounted on to the custom shoulder simulator. The first condition to be tested was the intact shoulder state, the second was after creating a massive, irreparable rotator cuff tear, the third was after inserting the subacromial balloon spacer and inflating to three different volumes; 10, 25 and 40 mL to represent under inflation, optimal and over inflation of the subacromial balloon spacer. Humeral head migration was measured at 0, 30, 60 and 90 degrees of static shoulder abduction for all five shoulder states.



*Torn:* For the massive, irreparable rotator cuff tear state, a surgically created tear was made through a deltoid splitting incision (Figure 2-3). A 3 cm longitudinal skin incision was made starting from the lateral edge of the acromion and continued distally. The rotator cuff footprint was accessed through this incision and a large full thickness postero-superior tear was created involving the entire supraspinatus and upper border of the infraspinatus tendon. From anterior to posterior, the surgical tear measured 5 cm. The subscapularis and teres minor tendons were not disrupted. Once the surgical tear was completed, the deltoid split was closed at the skin with #5 Ethibond sutures.

*Balloon:* After the torn state was cycled through testing, the deltoid split was re-opened and the subacromial balloon spacer was inserted through this incision. There are three different sizes of balloons to insert based on the size of the subacromial space. The subacromial space size of each specimen was measured from the greater tuberosity to 1 cm medial to the superior glenoid rim. All eight cadavers had a subacromial space measuring greater than or equal to 5 cm, which equated to the large balloon size. The large balloon was inserted using an introducing tube (Figure 3-1), which was placed 1 cm medial to the glenoid rim. The tube was retracted and the balloon was inflated in the subacromial space using saline. The balloon was sealed and separated from the device handle. The balloon insertion system was removed and the balloon was left in situ. The deltoid split was closed at the skin using #5 Ethibond. Three different conditions of balloon inflation (10, 25 and 40 mL) were tested in a randomized fashion on each specimen.



**Figure 3-1 Subacromial Balloon Spacer**

*The subacromial balloon spacer is shown attached to the device insertion handle and the syringe filled with normal saline allows titration of various fill volumes for the balloon.*

**3.2.3 Outcome Variables**

The main outcome variable tested in this study was humeral head migration (anterior-posterior and superior-inferior).

Five different shoulder states were tested; **intact**, **torn** (after inducing a massive, irreparable rotator cuff tear) and **balloon at 10, 25 and 40 mL** (after inserting the subacromial balloon space and inflating to three different volumes in a randomized method; 10, 25 and 40 mL).

Superior humeral head migration was a surrogate measurement for a clinical symptom complex, known as subacromial impingement. Each outcome variable was tested at 0, 30, 60 and 90 degrees of static shoulder abduction for each shoulder state. The anterior-posterior and superior-inferior humeral head migration was measured using the optical tracking system. Using a reference coordinate system for each specimen, the relative motion of the humeral head compared to the centre of the glenoid was measured in millimetres.

#### 3.2.4 Statistical Analysis

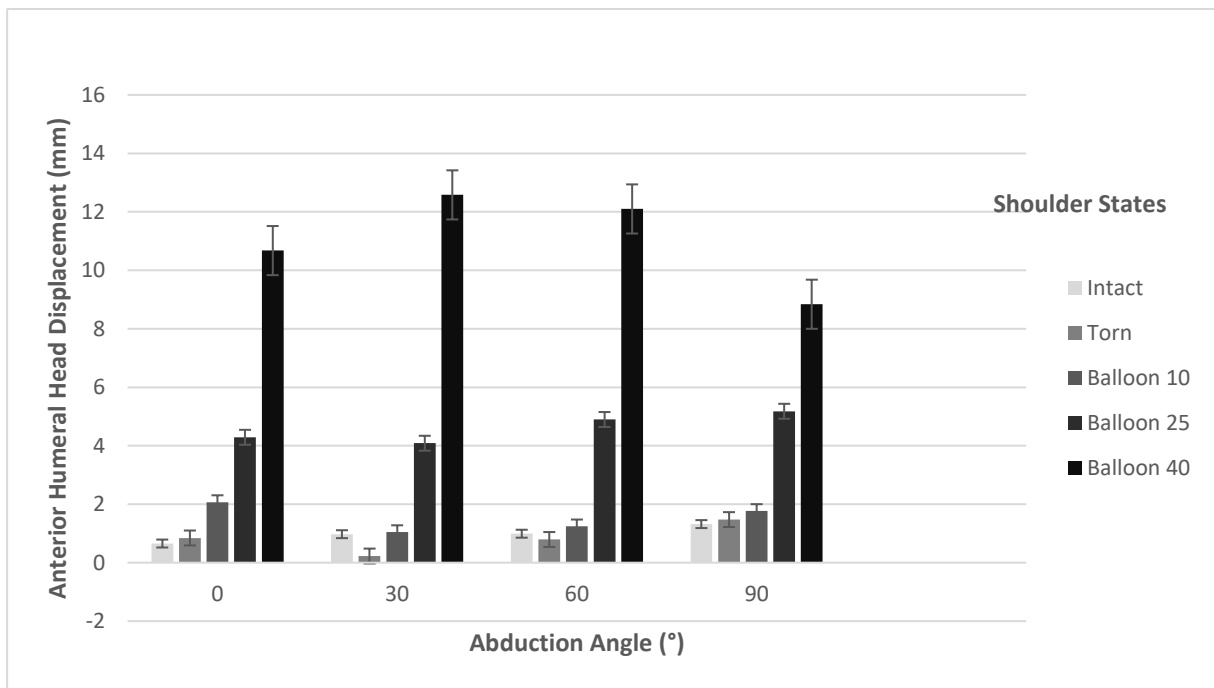
The varying abduction angles (0°, 30°, 60° and 90°), shoulder states (intact, torn, balloon at 10, 25 and 40 mL inflation volumes) and deltoid loads (40 and 80 N) were tested as independent variables, with humeral head migration (both superior-inferior and anterior-posterior) being the primary outcome measurement. Repeated measures of analysis of variance was done for statistical analysis, with Bonferroni correction used for the multiple comparisons made and statistical significance was set as  $p < 0.05$ .

### 3.3 Results

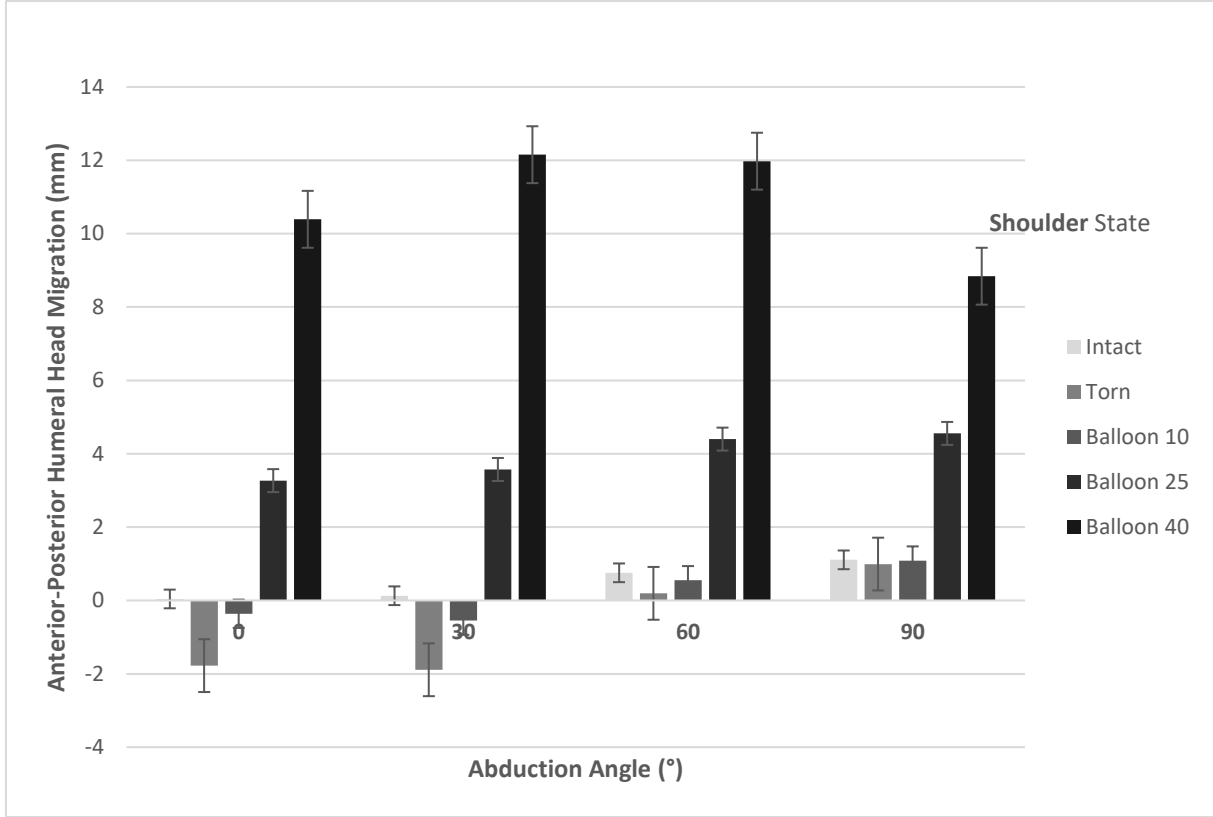
#### 3.3.1 Anterior-Posterior Humeral Head Migration

##### 3.3.1.1 Shoulder State

Five different shoulder states were tested; intact shoulder, after creating a massive, irreparable postero-superior rotator cuff tear, and after insertion of the subacromial balloon spacer inflated to three different volume states (10, 25 and 40 mL). The summary of the results is shown in Figure 3-2 and Figure 3-3.



**Figure 3-2 Anterior-Posterior Humeral Head Migration Results at 40 N Deltoid Load**  
*The mean  $\pm$  1 SD of the anterior humeral head migration for the various shoulder states (intact, torn, balloon at 10, 25 and 40 mL) and shoulder abduction angles (0,30,60 and 90°) are shown in the figure. These results are shown with the deltoid activated at 40 N.*



**Figure 3-3 Anterior-Posterior Humeral Head Migration Results at 80 N Deltoid Load**

The mean  $\pm$  1 SD of the anterior-posterior humeral head migration for the various shoulder states (intact, torn, balloon at 10, 25 and 40 mL) and shoulder abduction angles (0,30,60 and 90°) are shown in the figure. These results are shown with the deltoid activated at 80 N. A positive value on the y axis represents anterior displacement and a negative value on the y axis represents posterior displacement.

Table 3.1 provides the mean difference in anterior humeral head translation between the various shoulder states. When considering all abduction angles together and both deltoid loads together, the balloon inflated at 25 mL and 40 mL significantly translated the humeral head anteriorly ( $p=0.011$  and  $p=0.001$ , respectively) as compared to the intact

state. The balloon at 40 mL translated the humeral head anteriorly by  $10.2 \pm 1.3$  mm, where as the balloon at 25 mL translated the humeral head anteriorly by  $3.6 \pm 0.7$  mm compared to the intact state. There was no significant difference between the anterior-posterior humeral head position when comparing the intact state to the torn state ( $p=0.641$ ) and to the balloon inflated to 10 mL ( $p= 1.000$ ).

Shoulder State	Mean Difference (mm)	Significance (P value)
Torn	$0.6 \pm 0.3$	0.641
Balloon at 10 mL	$0.1 \pm 0.2$	1.000
Balloon at 25 mL	$3.6 \pm 0.7$	0.011
Balloon at 40 mL	$10.2 \pm 1.3$	0.001

**Table 3.1 Anterior Humeral Head Displacement**

*This table provides the mean difference in anterior humeral head displacement (mm) between the various shoulder states as compared to the intact state. A significant value was  $p<0.05$ .*

When comparing the torn shoulder state to the other shoulder states, there was no significant differences between the intact state ( $p=0.641$ ) and the balloon at the 10 mL level ( $p=0.312$ ) in terms of anterior-posterior humeral head displacement. Similar to the intact state, there was a significant difference between the torn state and the balloon at 25 mL ( $p=0.003$ ) and 40 mL ( $p=0.001$ ).

At  $0^\circ$  of shoulder abduction, there was a significant displacement of the humeral head anteriorly when the balloon was inserted and inflated at 25 mL ( $p=0.024$ ) and 40 mL ( $p=0.003$ ) when compared to the intact state. This anterior humeral head displacement was

also significant when comparing the torn state to the balloon at 25 mL and 40 mL at 0° of shoulder abduction ( $p=0.005$  and  $p=0.002$ , respectively). Finally, the anterior displacement of the humeral head was also significant when comparing the balloon at 10 mL to the balloon at 25 mL and 40 mL at 0° of shoulder abduction ( $p=0.004$  and  $p=0.001$ , respectively). There was no difference between the humeral head position (anterior-posterior) at 0° of shoulder abduction between the intact, torn and balloon at 10 mL state ( $p=1.000$ ). This was true for all abduction angles; 0°, 30°, 60°, and 90° and when comparing shoulder states within each deltoid load 40 and 80 N.

### 3.3.1.2 Abduction Angle

Four different static shoulder abduction angles were tested; 0°, 30°, 60° and 90°. When considering all shoulder states together and both deltoid loads, the varying abduction angles did not have a significant difference on the anterior-posterior humeral head position ( $p=1.000$ ).

Furthermore, when comparing the four abduction angles within each shoulder state, there was no significant difference on anterior-posterior humeral head displacement in the intact, torn balloon at 10 mL and balloon at 25 mL state ( $p=1.000$ ). However, when the balloon was inflated at 40 mL, there was a significant difference in the humeral head position when comparing 0° and 30° of shoulder abduction ( $p=0.001$ ). The humeral head

was displaced anteriorly an average of  $1.8 \pm 0.3$  mm when the shoulder was abducted from  $0^\circ$  to  $30^\circ$ .

When the deltoid was loaded at 40 N, there was no significant difference between the anterior-posterior positioning of the humeral head at the varying abduction angles ( $p=1.000$ ). When the various abduction angles were compared with the deltoid muscle activated at 80 N, there was also no significant difference in the humeral head position ( $p=1.000$ ).

### 3.3.1.3 Deltoid Load

When considering all shoulder states and all abduction angles, loading the deltoid muscle at 40 and 80 N did have a significant difference in humeral head displacement ( $p=0.013$ ). With the deltoid muscle fired at 80 N, the humeral head was on average displaced posteriorly by  $0.8 \pm 0.3$  mm.

At  $0^\circ$  and  $30^\circ$  of shoulder abduction, there was a significant difference in the humeral head position with the deltoid activated at 40 N vs 80 N ( $p=0.002$  and  $p=0.011$ , respectively). When the deltoid load was increased from 40 to 80 N at  $0^\circ$  of abduction, the humeral head position was translated posteriorly  $1.4 \pm 0.3$  mm. At  $30^\circ$  of abduction, when



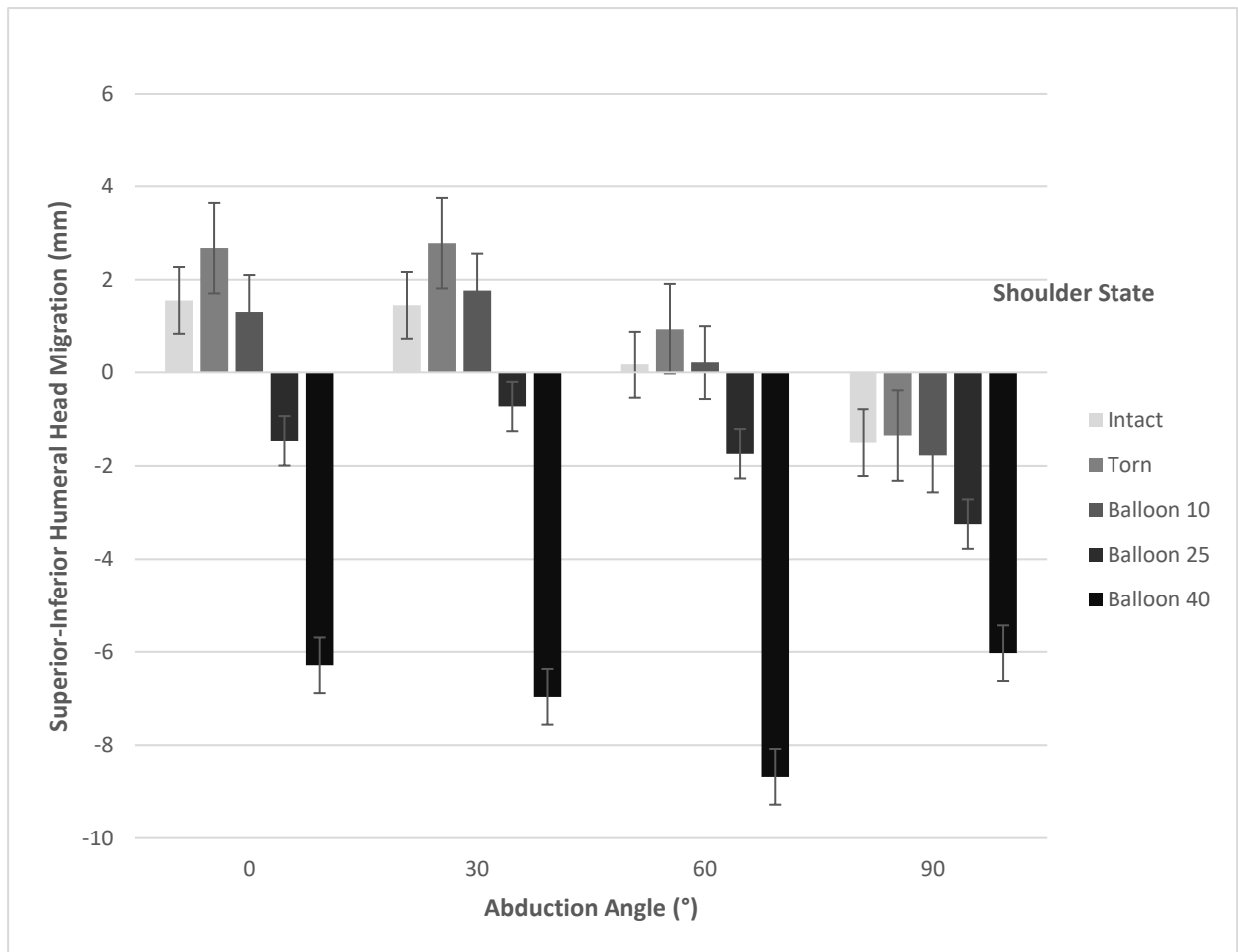
the deltoid activation increased from 40 to 80 N, the humeral head position was posteriorly translated by  $1.1 \pm 0.3$  mm. The deltoid load was not significant in posterior humeral head translation at 60° and 90° of shoulder abduction ( $p=0.192$  and  $p=0.275$ , respectively).

When increasing the deltoid load from 40 to 80 N, there was a significant difference in the humeral head position in the intact ( $p=0.012$ ), torn ( $p=0.007$ ) and balloon at 10 mL ( $p=0.003$ ) shoulder state. The humeral head was translated posteriorly with increasing deltoid load at these three shoulder states. No significant differences were noted in the humeral head position when the balloon was inflated to 25 mL ( $p=0.069$ ) and 40 mL ( $p=0.489$ ) with varying deltoid loads.

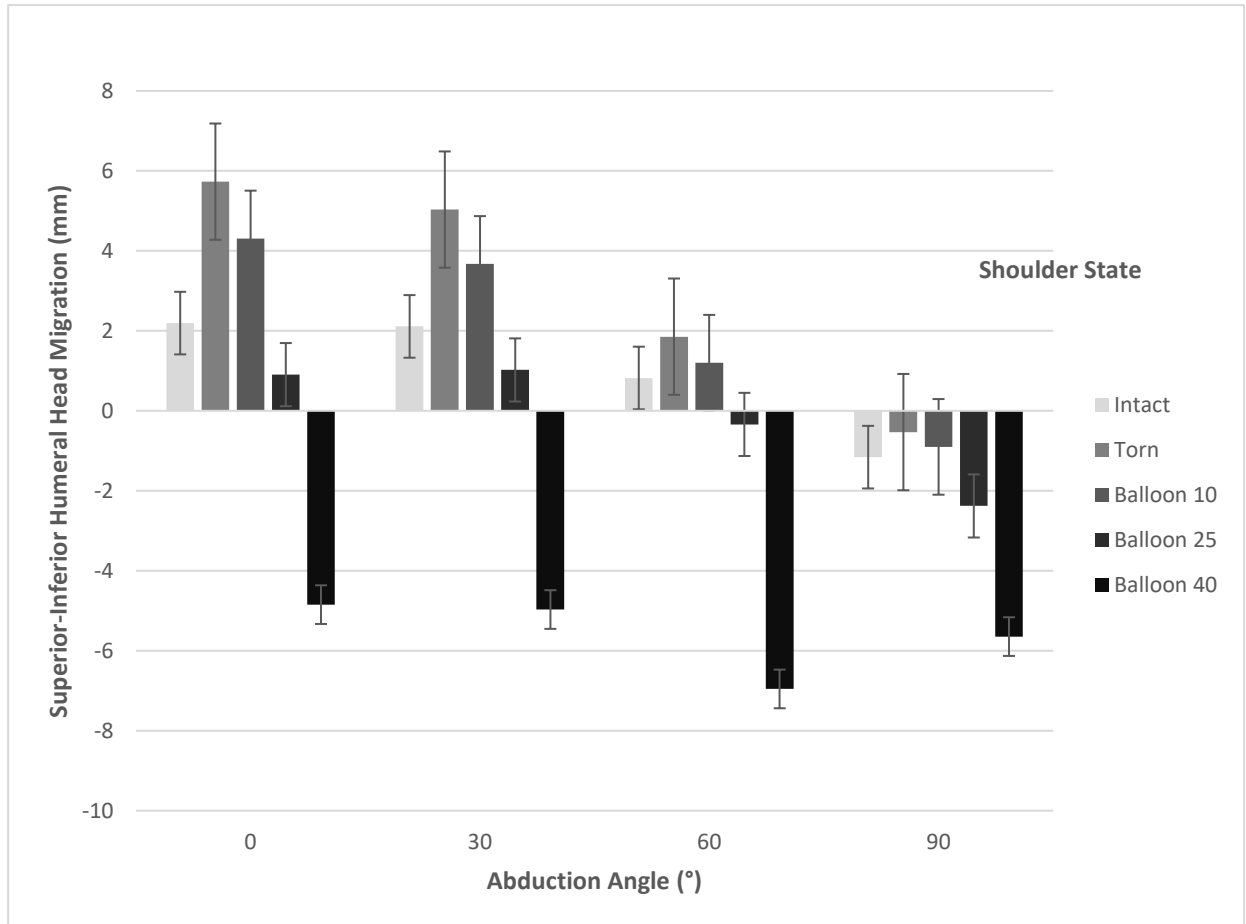
### 3.3.2 Superior-Inferior Humeral Head Migration

#### 3.3.2.1 Shoulder State

When considering all abduction angles and both deltoid loads (40 and 80 N) together, there was a significant difference between the superior-inferior humeral head position between the shoulder states. Figure 3-4 and Figure 3-5 illustrate the summary of the results for superior-inferior humeral head migration.



**Figure 3-4 Superior-Inferior Humeral Head Migration Results at 40 N Deltoid Load**  
*The mean  $\pm$  1 SD of the superior-inferior humeral head migration for the various shoulder states (intact, torn, balloon at 10, 25 and 40 mL) and shoulder abduction angles (0,30,60 and 90°) are shown in the figure. These results are shown with the deltoid activated at 40 N. A positive value on the y axis represents superior displacement and a negative value on the y axis represents inferior displacement.*



**Figure 3.5 Superior-Inferior Humeral Head Migration Results at 80 N Deltoid Load**  
*The mean  $\pm$  1 SD of the superior-inferior humeral head migration for the various shoulder states (intact, torn, balloon at 10, 25 and 40 mL) and shoulder abduction angles (0,30,60 and 90°) are shown in the figure. These results are shown with the deltoid activated at 80 N. A positive value on the y axis represents superior displacement and a negative value on the y axis represents inferior displacement.*

After creating the massive, irreparable rotator cuff tear, there was an average superior migration of the humeral head by  $1.4 \pm 0.4$  mm ( $p=0.046$ ) as compared to the intact state. There were no significant differences between the intact state and the balloon at 10 mL ( $p=1.000$ ) and the intact state and the balloon at 25 mL ( $p=0.118$ ) in terms of superior-inferior humeral head migration. When the subacromial balloon spacer was inflated to 40 mL, the humeral head was translated inferiorly by  $7.0 \pm 1.2$  mm ( $p=0.007$ ) relative to the intact state.

There was a significant difference in the humeral head position between the torn state and all other shoulder states (see Table 3.2). The humeral head was translated inferiorly by all shoulder states as compared to the torn state.

Shoulder State	Inferior Humeral Head Migration (mm)	Significance (P value)
Intact	$1.4 \pm 0.4$	0.046
Balloon at 10 mL	$0.9 \pm 0.2$	0.046
Balloon at 25 mL	$3.1 \pm 0.6$	0.013
Balloon at 40 mL	$8.4 \pm 1.2$	0.002

**Table 3.2 Superior-Inferior Humeral Head Migration**

*This table demonstrates the mean difference in humeral head position between the various shoulder states as compared to the torn shoulder state.*

When the balloon was inflated to 10 mL, the humeral head position was not significantly different as compared to the intact state ( $p=1.000$ ). However, the balloon at 10 mL inflation was significantly different than the torn state ( $p=0.046$ ), the balloon at 25

mL ( $p=0.012$ ) and the balloon at 40 mL ( $p=0.003$ ). The humeral head was translated superiorly after the tear ( $0.9 \pm 0.2$  mm) and was translated inferiorly by the balloon inflated to 25 ( $2.2 \pm 0.4$  mm) and 40 mL ( $7.5 \pm 1.1$  mm) as compared to the balloon at 10 mL.

When the subacromial balloon spacer was inflated to 25 mL, the ideal recommended volume, there was no significant difference between this state and the intact state ( $p=0.118$ ). When comparing the balloon at 25 mL to the torn state, the humeral head migrated superiorly by  $3.1 \pm 0.6$  mm ( $p=0.013$ ) after the tear. When the balloon was deflated from 25 mL to 10 mL, the humeral head migrated superiorly by  $2.2 \pm 0.4$  mm ( $p=0.012$ ). Finally, when the balloon was inflated from 25 mL to 40 mL, the humeral head was translated inferiorly by  $5.3 \pm 1.0$  mm ( $p=0.009$ ).

The humeral head position was significantly different when the balloon inflated to 40 mL as compared to all other shoulder states. The balloon at 40 mL translated the humeral head inferiorly compared to all other shoulder states.

When comparing the shoulder states within each abduction angle, it was determined that there were no significant differences between the superior-inferior humeral head translation from the intact state to the balloon at 10 mL ( $p=1.000$ ) and from the intact state to the balloon at 25 mL ( $p=0.538$ ) at  $0^\circ$  of shoulder abduction. A significant difference was

appreciated between the intact and torn state ( $p=0.049$ ), with the humeral head migrating superiorly by  $2.3 \pm 0.6$  mm in the torn state at  $0^\circ$  of shoulder abduction. A significant difference was also noted between the intact shoulder state and the balloon inflated to 40 mL ( $p=0.019$ ), with the humeral head being translated inferiorly by  $7.5 \pm 1.5$  mm by the balloon at 40 mL  $0^\circ$  of shoulder abduction.

As the abduction angle increased, the main finding noted was that a significant difference between the balloon at 10 mL and the balloon at 25 mL developed. At  $30^\circ$ ,  $60^\circ$  and  $90^\circ$  of shoulder abduction, the balloon at 25 mL was able to significantly depress the humeral head as compared to the balloon at 10 mL ( $p=0.027$ ,  $p=0.030$  and  $p=0.034$ , respectively).

Finally, as the abduction angle reached  $90^\circ$ , the significant superior-inferior humeral head position differences were eliminated between the shoulder states.

### 3.3.2.2 Abduction Angle

When considering all shoulder states and both deltoid loads together, as the abduction angle increased, the humeral head position was translated inferiorly. There was no significant difference in the humeral head position when comparing  $0^\circ$  to  $30^\circ$  of shoulder

abduction. However, from 0° to 60° of shoulder abduction, the humeral head was translated inferiorly by  $1.9 \pm 0.4$  mm ( $p=0.019$ ). Also, from 0° to 90° of abduction, the humeral head was translated inferiorly by  $3.1 \pm 0.7$  mm ( $p=0.016$ ). When the shoulder was abducted from 30° to 60°, the humeral head migrated inferiorly  $1.8 \pm 0.2$  mm ( $p<0.001$ ). Also, when the shoulder was abducted from 30° to 90°, the humeral head migrated inferiorly  $3.0 \pm 0.5$  mm ( $p=0.005$ ). There was no significant difference in humeral head position from 60° to 90° of shoulder abduction ( $p=0.195$ ).

When abduction angle was examined within each shoulder state, there was no significant difference in the superior-inferior humeral head migration from 0° to 30° of shoulder abduction ( $p=1.000$ ), however, there was a significant difference between all other abduction angles. This was consistent for the intact shoulder state, the torn shoulder state, and the balloon inflated to 10 mL state. When the balloon was inflated to 25 mL, the only significant changes in the humeral head position occurred from 30° to 90° ( $p=0.036$ ) and from 60° to 90° ( $p=0.034$ ). When the shoulder was abducted from 30° to 90°, the balloon at 25 mL caused depression of the humeral head by  $3.0 \pm 0.8$  mm. Furthermore, when the shoulder was abducted from 60° to 90°, the balloon at 25 mL caused the humeral head to translate inferiorly by  $1.8 \pm 0.5$  mm. Finally, when the humeral head position was compared at various abduction angles with the balloon inflated to 40 mL, there were no significant differences noted ( $p=1.000$ ).

When the deltoid muscle was activated to 40 N, increasing the abduction angle did not have a significant impact on the superior-inferior migration of the humeral head ( $p=1.000$ ). However, when the deltoid muscle load was increased to 80 N, then the superior-inferior humeral head migration was significant at each abduction angle.

### 3.3.2.3 Deltoid Load

There was a significant difference in the superior-inferior humeral head position caused by the increase in deltoid load from 40 to 80 N, when considering all shoulder states and abduction angles together. The humeral head migrated superiorly on average  $1.4 \pm 0.1$  mm, when the deltoid load was increased from 40 to 80 N ( $p<0.001$ ).

When evaluating deltoid muscle force at each abduction angle, there was significant superior humeral head migration when the deltoid muscle was fired at 80 N (see Table 3.3).

Abduction Angle	Superior Humeral Head Migration (mm)	Significance (P Value)
0°	$2.1 \pm 0.3$	< 0.001
30°	$1.7 \pm 0.2$	< 0.001
60°	$1.1 \pm 0.1$	< 0.001
90°	$0.7 \pm 0.2$	0.020

**Table 3.3 Impact of Deltoid Force on Humeral Head Migration based on Abduction Angles**

*This table shows the mean difference in superior humeral head migration (in mm) when the deltoid muscle is increased from 40 to 80 N within each abduction angle.*



When the deltoid force was increased from 40 to 80 N within each shoulder state, there was also significant superior humeral head migration (see Table 3.4).

Shoulder State	Superior Humeral Head Migration (mm)	Significance (P Value)
Intact	0.6 ± 0.1	< 0.001
Torn	1.8 ± 0.3	0.001
Balloon at 10 mL	1.7 ± 0.2	< 0.001
Balloon at 25 mL	1.6 ± 0.2	< 0.001
Balloon at 40 mL	1.4 ± 0.2	< 0.001

**Table 3.4 Impact of Deltoid Force on Humeral Head Migration based on Shoulder State**

*This table shows the mean difference in superior humeral head migration (in mm) when the deltoid muscle is increased from 40 to 80 N within each shoulder state.*

Overall, we can conclude that the deltoid muscle plays a significant role in superior humeral head migration.

## 3.4 Discussion

### 3.4.1 Anterior-Posterior Humeral Head Migration

The purpose of this study was to biomechanically evaluate the subacromial balloon spacer to determine its effectiveness as a device in restoring humeral head position after a massive, irreparable rotator cuff tear. Both anterior-posterior and superior-inferior humeral head migration was examined. When the subacromial balloon spacer was inflated to 25 mL and 40 mL, the humeral head was displaced anteriorly as compared to the intact shoulder state. The overinflated balloon state (40 mL) displaced the humeral head anteriorly approximately  $10.2 \pm 1.3$  mm, where as the recommended volume (25 mL) only displaced the humeral head anteriorly by  $3.6 \pm 0.7$  mm as compared to the intact state. Both of these were statistically significant, perhaps indicating that underinflating the balloon may prevent anterior humeral head displacement. The clinical relevance of a small amount of anterior humeral head displacement is unclear. However, in clinical scenarios with a disrupted subscapularis, anterior translation may be poorly tolerated by the patient.

Based on the results of this study, creating a massive, irreparable postero-superior rotator cuff tear does not significantly affect the anterior-posterior positioning of the humeral head from the intact state. This can be explained by the fact that the subscapularis and part of the posterior cuff remains intact and would prevent anterior to posterior translation as opposed to superior-inferior. However, when the balloon is inserted and

inflated, this study shows that the inflation volume is correlated to anterior humeral head displacement. In terms of anterior-posterior humeral head displacement, shoulder state did affect humeral head position.

On the contrary, changing the abduction angle alone, did not impact anterior-posterior humeral head displacement. When the shoulder was abducted, there was no significant anterior-posterior humeral head displacement and this was likely due to the intact anterior cuff and partial posterior cuff. Without the loading of the deltoid muscle, the humeral head stays relatively centered in the anterior-posterior direction with increasing abduction angle. The exception to this, was when the balloon was inflated to 40 mL. When the subacromial balloon spacer was overinflated, increasing the abduction angle, did affect anterior humeral head displacement. The effect of anterior humeral head displacement was likely due to the overinflation of the balloon as opposed to the abduction angle alone, as this effect was not seen in any other shoulder state.

In addition, when increasing the deltoid muscle load from 40 to 80 N, the humeral head was displaced posteriorly by less than 1 mm, however, this was statistically significant ( $p=0.013$ ). When the deltoid muscle load is increased, the sum of the vector forces from the deltoid muscle is directed superiorly. In this study, a postero-superior rotator cuff tear was induced, creating a deficiency in the posterior and superior cuff. The subscapularis

muscle was left completely intact and thus may account for the posterior humeral head displacement with increasing deltoid muscle load. The posterior displacement was primarily seen in the torn state and the balloon at 10 mL, when the balloon was inflated to 25 and 40 mL, the posterior displacement was eliminated. The inflated balloon states displace the humeral head anteriorly and thus no posterior displacement was present. The anterior humeral head displacement was likely caused when the balloon was inflated maximally due to the balloon position in the subacromial space. After creation of a massive postero-superior rotator cuff tear, with increasing inflation, the balloon was more posteriorly positioned, thus physically displacing the humeral head anteriorly.

Overall, the anterior-posterior humeral head displacement was caused by the shoulder state, in particular, the balloon inflated to 25 mL and 40 mL caused anterior humeral head displacement. Abduction angle and deltoid load alone were not major contributors to anterior-posterior humeral head displacement. This would suggest that, underinflation as opposed to over inflation of the balloon would lead to less anterior-posterior translation of the humeral head.

### 3.4.2 Superior-Inferior Humeral Head Migration

The primary role of the subacromial balloon spacer is depression of the humeral head in the setting of a massive, irreparable postero-superior rotator cuff tear. In this study, shoulder state, abduction angle and deltoid load were examined and superior-inferior humeral head migration was measured. As noted in Chapter 2, shoulder state had a significant impact on superior humeral head migration, this was redemonstrated in chapter 3. After inducing a massive, irreparable rotator cuff tear, the humeral head migrated superiorly by  $1.4 \pm 0.4$  mm as compared to the intact shoulder state. This significant superior humeral head migration was restored to the intact shoulder position after inserting the subacromial balloon spacer inflated at 10 mL and 25 mL. Over inflation of the balloon spacer to 40 mL caused significant depression of the humeral head as compared to all other shoulder states. When specifically comparing the balloon inflated to 10 mL as compared to the balloon at 25 mL, the balloon at 25 mL was able to significantly depress the humeral head as compared to the balloon at 10 mL at increasing abduction angles ( $p=0.041$ ). Therefore, the balloon at 25 mL is likely better able to reduce the humeral head as compared to the balloon at 10 mL in varying abduction angles.

All three balloon fill volumes caused depression of the humeral head, however, only the balloon at 10 mL and 25 mL restored the humeral head position to the intact state. The balloon is a space occupying device and when inflated to increasing volumes, it creates

increasing depression of the humeral head. Over inflation of the subacromial space, causes supraphysiologic depression of the humeral head and likely influences glenohumeral joint kinematics by overstuffing this joint space. Ideal inflation of the large balloon restores the humeral head to the intact position.

In addition to shoulder state, abduction angle also had an effect on the superior-inferior humeral head positioning. As the abduction angle increased, the humeral head translated inferiorly. This difference was most notable when the shoulder was abducted from  $0^{\circ}$  to  $60^{\circ}$  and from  $0^{\circ}$  to  $90^{\circ}$ . Based on the anatomy reviewed in chapter 1, to allow for shoulder abduction, the humeral head must move inferiorly. When the subacromial balloon spacer inflated to 40 mL was inserted, the superior-inferior humeral head motion was eliminated at all abduction angles. This may be explained by the fact that the subacromial space would be overstuffing with the balloon at 40 mL reducing the humeral head's ability to move within that space.

The magnitude of the deltoid load also resulted in a significant effect on the superior-inferior humeral head positioning. This was demonstrated in Chapter 2 as well. When the deltoid muscle load was increased from 40 to 80 N, the humeral head migrated superiorly. This may be explained by the sum of the vector forces of the deltoid muscle. As described in Chapter 1, the deltoid muscle is composed of anterior muscle fibers

responsible for forward flexion and posterior fibers responsible for extension. The lateral muscle fibers are responsible for abduction and when activated create a superior directed force on the humeral head. At 80 N, the deltoid muscle is able to cause significant superior humeral head migration in all shoulder states, at all abduction angles. This chapter demonstrates again that shoulder state, abduction angle and deltoid load have a significant effect on superior-inferior humeral head migration.

### 3.4.3 Strengths & Limitations

This is the first biomechanical assessment of the subacromial balloon spacer. No other studies have examined this device in the lab and tested the mechanics of various inflation volumes. The stated purpose of the balloon is to depress the humeral head and prevent subacromial impingement. This study quantifies the humeral head migration after insertion of the balloon spacer and may guide clinical use of this device in the future.

It is important to highlight some of the limitations of this cadaveric study. Static abduction was the only plane of motion tested and although it is representative of glenohumeral joint motion, it does not capture the multiaxial nature of the joint. In addition, although anterior-posterior and superior-inferior humeral head migration were measured, the clinical relevance of the migration is not known. Although superior humeral head

migration is likely reflective of subacromial impingement, the amount of inferior, anterior and posterior translation does not necessarily correlate with specific functional deficits. Finally, the role of the long head of the biceps in preventing anterior-posterior translation was not examined in this study. The biceps tendon was removed during the creation of the rotator cuff tear and perhaps it may play a role in preventing anterior-posterior translation if left intact.

### 3.5 Conclusion

This is the first biomechanical study to examine the subacromial balloon spacer as a treatment for massive, irreparable rotator cuff tears. This study evaluated the role and effectiveness of the subacromial balloon spacer as a device in depressing the humeral head and restoring glenohumeral joint kinematics. In this study, three independent variables were examined. The independent variables included five shoulder states, four abduction angles and two deltoid muscle loads. The shoulder states included the intact shoulder, the shoulder after creating a massive, irreparable rotator cuff tear, and then the shoulder after inserting the subacromial balloon spacer inflated to three different volumes (10, 25 and 40 mL). The three volumes correspond to under inflation, ideal/recommended inflation and over inflation volumes for the large balloon spacer. Each shoulder state was tested at four different shoulder abduction angles ( $0^\circ$ ,  $30^\circ$ ,  $60^\circ$  and  $90^\circ$ ). The deltoid was loaded to both 40 and 80 N for each shoulder state and each abduction angle. Finally, humeral head



migration, both anterior-posterior and superior-inferior, was the primary outcome measured.

The results of this study showed that after inducing a massive, irreparable rotator cuff tear, the humeral head migrated superiorly as compared to the intact state. The subacromial balloon spacer at 10 mL and 25 mL restored the humeral head position to the intact state. The balloon at 25 mL did translate the humeral head more anteriorly as compared to the intact state. Overinflation of the balloon caused significant displacement of the humeral head anteriorly and inferiorly. Finally, as shown in Chapter 2, the deltoid muscle played a significant role in causing superior humeral head migration when loaded to 80 N.

This study demonstrates that the balloon can effectively depress the humeral head. Overinflation of the balloon should be avoided to prevent anterior displacement of the humeral head, as well as, to prevent overstuffing the glenohumeral joint. Further studies should be performed to understand how humeral head migration impacts patients clinically, in terms of range of motion and activities of daily living. At this point, based on the evidence from previous studies and this biomechanical study, the subacromial balloon spacer may be considered as an effective treatment option for massive, irreparable rotator cuff tears.

### 3.6 References

Anley, C., Chan, S.K.L., Snow, M. (2014). Arthroscopic treatment options for irreparable rotator cuff tears of the shoulder. *World Journal of Orthopedics*, 5, 557-565.

Deranlot, J., Herisson, O., Nourissat, G., Zbili, D., Werthel, J. D., Vigan, M., & Bruchou, F. (2017). Arthroscopic Subacromial Spacer Implantation in Patients With Massive Irreparable Rotator Cuff Tears: Clinical and Radiographic Results of 39 Retrospectives Cases. *Arthroscopy: The Journal of Arthroscopic and Related Surgery*.

Gerber, C., Wirth, S.H., Farshad, M. (2011). Treatment options for massive rotator cuff tears. *Journal of Shoulder and Elbow Surgery*, 20, S20-S29

Kilinc, A. S., Ebrahimzadeh, M. H., & Lafosse, L. (2009). Subacromial internal spacer for rotator cuff tendon repair: “The balloon technique”. *Arthroscopy: The Journal of Arthroscopic and Related Surgery*, 25(8), 921-924.

Ramot, Y., Nyska, A., Markovitz, E., Dekel, A., Klaiman, G., Zada, M. H., Maronpot, R. R. (2015). Long-term local and systemic safety of poly(l-lactide-co-epsilon-caprolactone) after subcutaneous and intra-articular implantation in rats. *Toxicologic Pathology*, 43(8), 1127-1140.

Savarese E, Romeo R. (2012). New solution for massive, irreparable rotator cuff tears: The subacromial “biodegradable spacer”. *The Journal of Arthroscopy Techniques*,1:69-74.

Senekovic, V., Poberaj, B., Kovacic, L., Mikek, M., Adar, E., Dekel, A. (2013). Prospective clinical study of a novel biodegradable subacromial spacer in treatment of massive irreparable rotator cuff tears. *European Journal of Orthopedic Surgery and Traumatology*, 23, 311-316.

Senekovic, V., Poberaj, B., Kovacic, L., Mikek, M., Adar, E., Dekel, A. (2016). The biodegradable spacer as a novel treatment modality for massive rotator cuff tears: a prospective study with 5-year follow-up. *Archives of Orthopedic and Trauma Surgery*.

Szöllösy, G., Rosso, C., Fogerty, S., Petkin, K., & Lafosse, L. (2014). Subacromial Spacer Placement for Protection of Rotator Cuff Repair. *Arthroscopy Techniques*, 3(5), 605–609.

## Chapter 4

### 4.1 Conclusions

The surgical management of massive, irreparable rotator cuff tears is challenging. The dilemma exists in a younger patient with no evidence of glenohumeral joint arthritis. The definitive treatment option proposed in the management algorithm in an older patient is a reverse total shoulder arthroplasty or a major open procedure such as a tendon transfer. Two new arthroscopic techniques have been proposed as possible treatment options. Superior capsular reconstruction and the insertion of a subacromial balloon spacer are both meant to restore humeral head position and shoulder kinematics. Both treatment options are less invasive surgeries than arthroplasty.

The purpose of this thesis was to compare these two new treatment options in the management of massive, irreparable rotator cuff tears. This is the first biomechanical study done that examines the subacromial balloon spacer and directly comparing the balloon spacer with superior capsular reconstruction.

The primary objectives of this thesis were:

1. To compare the superior capsular reconstruction and the subacromial balloon spacer in their ability to prevent superior humeral head migration.
2. To compare both techniques in their impact on functional abduction forces; an indirect measure of shoulder abduction strength.
3. To examine the subacromial balloon spacer in its ability to function as a device; comparing fill volumes and their ability to prevent humeral head translation.

The goal was that these biomechanical studies would add to the current literature and yield important information to help guide future treatment of massive, irreparable rotator cuff tears.

## 4.2 *Summary of Chapter 2: A Comparison of Superior capsular reconstruction to the Subacromial Balloon Spacer*

The purpose of this study was to directly compare the superior capsular reconstruction to the subacromial balloon spacer in the treatment massive, irreparable rotator cuff tears. This biomechanical study compared humeral head migration and functional abduction force at varying degrees of shoulder abduction.

The hypothesis of this study was:

1. That both techniques would restore humeral head position to the native state at lower shoulder abduction angles, however, at higher abduction angles, the subacromial balloon spacer would better restore humeral head position as compared to superior capsular reconstruction.

The rationale for this hypothesis was that at higher abduction angles, the static capsule would not be able to contract to help prevent superior humeral head migration. The results of this study showed that both techniques are to the intact shoulder state regardless of abduction angle. The resultant deltoid force at lower abduction angles caused superior humeral head migration but at higher angles, the resultant force was directed more into axial joint compression and less superior directed. Thus, this may explain why no

differences were seen at increasing abduction angles between the superior capsular reconstruction and the subacromial balloon spacer.

In terms of functional abduction force, the hypothesis was:

2. That the functional abduction force would be lower in the torn state and restored to the intact state with both the superior capsular reconstruction and the subacromial balloon spacer.

This hypothesis was proven to be correct as abduction strength was restored and there were no differences in the extra force applied by the deltoid and rotator cuff muscles to abduct the arm with either treatment intervention as compared to the intact shoulder state.

This is the first biomechanical study to directly compare the superior capsular reconstruction to the subacromial balloon spacer. Both techniques functioned well to restore humeral head position and functional abduction forces as compared to the native shoulder. Further clinical studies are needed to evaluate if this restoration of humeral head position and abduction force is consistent with clinical improvement in pain and return to function.

### 4.3 *Summary of Chapter 3: A Biomechanical Study of the Subacromial Balloon Spacer in the Treatment of Massive, Irreparable Rotator Cuff Tears*

This study investigated the mechanics of the subacromial balloon spacer and evaluated various inflation volumes in the treatment of massive, irreparable rotator cuff tears. The purpose of this study was to evaluate the subacromial balloon spacer at a biomechanical level and examine its ability to depress the humeral head and prevent superior humeral head migration.

The hypothesis of this study was:

3. That optimal inflation of the subacromial balloon will be important in maintaining humeral head positioning. Over inflation or under inflation will lead to suboptimal humeral head positioning in the glenoid fossa and affect shoulder kinematics.

This hypothesis was partially accepted in that ideal inflation AND under inflation restored the humeral head position to the intact state. Although optimal inflation did displace the head more anteriorly, it also translated it more inferiorly as compared to the under inflation state. The results of this study show inflation of the large balloon spacer from 10-25 mL adequately restores humeral head position to the native state. Over inflation



of the balloon (>40 mL) should be avoided to prevent overstuffing the glenohumeral joint and anterior translation of the humeral head.

Overall, this was the first biomechanical study evaluating the subacromial balloon spacer and the results of this study prove it is an effective device in depressing the humeral head.

## 4.4 Future Directions

Taking into consideration that the superior capsular reconstruction and the subacromial balloon spacer were equally effective in this study at depressing the humeral head and restoring humeral head positioning in varying degrees of shoulder abduction. Further clinical studies need to examine the clinical results of these two techniques to compare complication and failure rates.

Furthermore, clinical studies examining the long term effects of these two procedures are needed. It is currently unclear how the subacromial balloon spacer maintains its effects on restoring humeral head position after disintegration. As well, there are no long term clinical studies on the effect of superior capsular reconstruction.

A randomized prospective clinical study should be done directly comparing the subacromial balloon spacer to the superior capsular reconstruction technique. If the balloon and superior capsular reconstruction are truly comparable in terms of clinical results for patients, then further cost analysis studies should be done. The subacromial balloon spacer is a low risk procedure that can be done in an outpatient clinic under local anesthetic in less than 20 minutes. This efficient procedure could have significant cost saving effects on the health care system. This could drastically change the management of massive, irreparable rotator cuff tears if clinical studies compare to the biomechanical studies.

## 4.5 Summary of Conclusions

Massive, irreparable rotator cuff tears are a complex surgical problem. The current treatment options vary from biceps tenotomy and subacromial decompression for pain relief to a reverse total shoulder arthroplasty as a definitive treatment option. This thesis examined two new treatment options for the subset of younger patients with no evidence of glenohumeral joint arthritis in the setting of a massive, irreparable rotator cuff tear. Both the superior capsular reconstruction and the subacromial balloon spacer prevent superior humeral head migration and restore humeral head position for optimal shoulder range of motion and function. Both treatment options are viable alternatives in the management of massive, irreparable rotator cuff. Based on the results of these studies, the subacromial balloon spacer and the superior capsular reconstruction technique are both effective humeral head depressors.

## APPENDIX A: Glossary of Terms

ABDUCTION	The movement of a limb away from the midline of the body.
ACROMIOHUMERAL DISTANCE	A measure of the space between the humeral head and the undersurface of the acromion (normal is 7-13mm).
ADDUCTION	The movement of a limb toward the midline of the body.
ANTERIOR	Especially situated in the front of the body.
ARTHROPLASTY	The replacement of a joint.
ARTHROSCOPY	The use of endoscopy (fiber-optic video camera) in a joint for visual examination, diagnosis and treatment of a joint problem.
ARTICULAR CARTILAGE	Cartilage covering the joint surface.

ARTICULATION

Also known as a joint (where two bones meet).

ATROPHY

The process of tissue wasting or degeneration.

BURSA

A fluid filled sac, usually countering friction at a joint.

BURSECTOMY

A surgical procedure involving removal of the bursa, usually carried out to relieve chronic inflammation (bursitis).

CIRCUMDUCTION

The circular movement of a limb, consists of a combination of flexion, extension, adduction and abduction.

CONSTANT SCORE

This score is a 100 point scale composed of parameters that assess pain, range of motion, strength and ability to carry out activities of daily living. The purpose of the score is to determine functionality after shoulder treatment.

CT SCAN	A computerized tomography scan, creates cross sectional imaging from a series of xrays taken from different angles.
DERMAL GRAFT	Also known as a skin graft.
DISTAL	Situated away from the center of the body.
FOOTPRINT	Anatomical location on the greater tuberosity where the rotator cuff muscles insert.
GLENOHUMERAL	Also known as the shoulder joint.
HETEROTOPIC OSSIFICATION	The presence of bone in soft tissue where bone does not normally exist.
LATERAL	A position farther away from the midline.
LOCAL ANESTHESIA	Anesthesia that affects a restricted area of the body.
MEDIAL	A position closer to the midline.

MULTI-AXIAL	A joint that moves in a number of axis, also known as polyaxial joint.
PERIPROSTHETIC	Refers to a structure in close relation to an implant.
POSTERIOR	Towards the rear of the body, also known as dorsal.
PROXIMAL	Located near to the point of attachment.
TENDONITIS	Inflammation of a tendon.
TENOTOMY	Surgical cutting of a tendon.
TENSOR FASCIA LATA	A muscle that arises from the pelvis and inserts on the iliotibial band.
TUBEROPLASTY	A reshaping procedure involving removal of exostoses (outgrowth of bone) on the humerus.
SALINE	A solution of salt in water.

SUBACROMIAL DEBRIDEMENT

A surgical procedure involving smoothing/shaving bone on the undersurface of the acromion. It can involve a bursectomy.

SUBACROMIAL DECOMPRESSION

Another term of subacromial debridement.

TRANSOSSEOUS

A term meaning through the bone.



## APPENDIX B: Superior Capsular Reconstruction Technique Guide



SHOULDER TECHNIQUE GUIDE

### Superior Capsule Reconstruction

Using the:

- Q-FIX® All-Suture Anchor
- HEALICOIL® REGENESORB Suture Anchor with ULTRATAPE® Suture
- MULTIFIX® S ULTRA Knotless Suture Anchor

As Described by: Martyn Snow, MD

KNEE

HIP

SHOULDER

EXTREMITIES

**As Described by:**

**Martyn Snow, MD**  
Consultant Orthopaedic Surgeon at  
The Royal Orthopaedic Hospital,  
Birmingham, United Kingdom.



## Superior Capsule Reconstruction

### Using the:

- Q-FIX® All-Suture Anchor
- HEALICOIL® REGENESORB Suture Anchor with ULTRATAPE® Suture
- MULTIFIX® S ULTRA Knotless Suture Anchor

*The following technique guide was prepared under the guidance of Martyn Snow, MD. Created under close collaboration with the surgeon, it contains a summary of medical techniques and opinions based upon his training and expertise in the field, along with his knowledge of Smith & Nephew's products. Smith & Nephew does not provide medical advice and recommends that surgeons exercise their own professional judgement when determining a patient's course of treatment. This guide is presented for educational purposes only. Prior to performing this technique, or utilizing any product referenced herein, please conduct a thorough review of each product's indications, contraindications, warnings, precautions and instructions as detailed in the instructions for Use provided with the individual components.*

### Patient Positioning

When performing Superior Capsule Reconstruction, it is recommended that the surgeon use the T-MAX Beach Chair and the SPIDER2 Limb Positioner. (Figure 1) The T-MAX Beach Chair can be attached to almost any OR table and allows for tilt, rotation, and forward/backward head movement. Additionally, the sliding back pad allows for unparalleled access to the surgical site. The SPIDER2 Limb Positioner allows for control of abduction, rotation, and forward flexion. It is recommended that the arm is positioned with the SPIDER2 Positioner in 15 to 20 degrees of abduction.

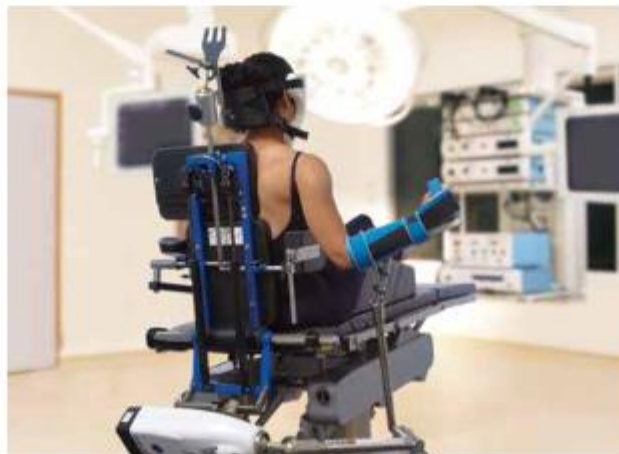

Figure 1

### Portal Placement

1. Drape the shoulder so that the surgeon has unrestricted access to the shoulder.
2. It is recommended that four portals are used with this technique: standard posterior, anterior, mid-lateral, and anterolateral working portal. (Figure 2)
3. Make a posterior skin incision 1.5 cm inferior and 1.5cm medial to the posterolateral border of the acromion to establish a **standard posterior portal** at the soft spot.
4. Insert a Smith & Nephew CLEAR-TRAC<sup>®</sup> COMPLETE Cannula and a blunt trocar through the posterior portal and into the glenohumeral joint. The glenohumeral joint is inspected, a standard anterior portal is created within the rotator interval and an 8.5mm cannula is inserted.
5. The subscapularis is confirmed to be intact and associated pathology is dealt with before the arthroscope is moved to the subacromial space.
6. A lateral portal is created at the midpoint of the acromion and a shaver used to clear the subacromial space.
7. The arthroscope is transferred to the lateral portal. An antero-lateral working portal is created 2-3cm inferior to the anterolateral corner of the acromion. A 10mm cannula is then inserted through the anterolateral portal and an 8.5mm cannula is inserted in the posterior portal.
8. The rotator cuff is released before confirming the rotator cuff is irreparable and proceeding with a superior capsule reconstruction.

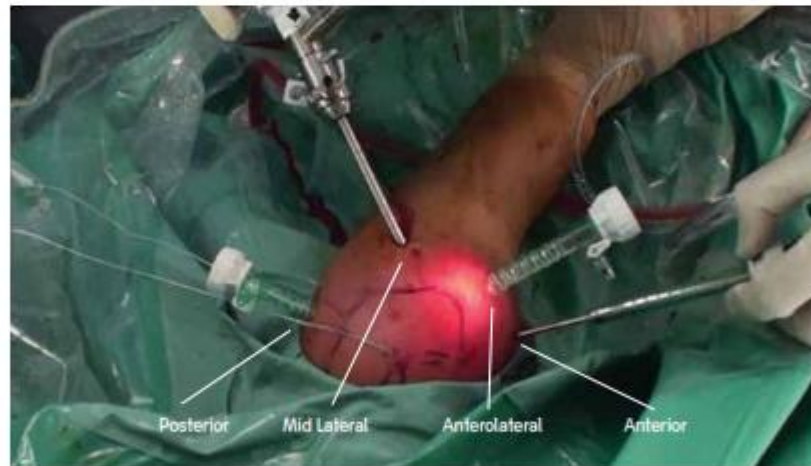


Figure 2



T-MAX  
Beach Chair  
Positioner



SPIDER2  
Limb Positioner



CLEAR-TRAC  
COMPLETE  
Disposable  
Cannula Systems

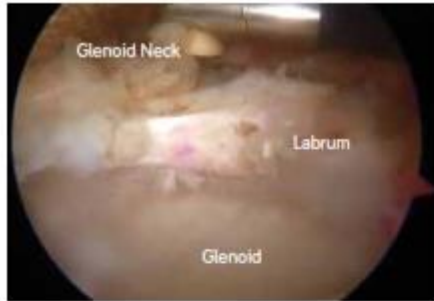


Figure 3

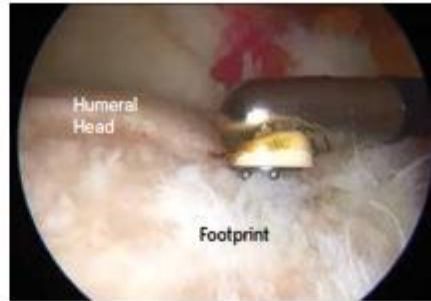


Figure 4

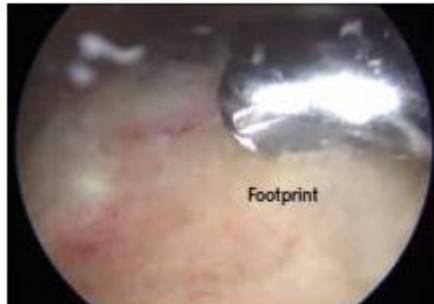


Figure 5

### Soft Tissue and Bone Preparation

1. After establishing the 4 portals, prepare the glenoid neck using a AMBIENT® SUPER TURBOVAC® 90 COBLATION® Wand (Figure 3) to remove soft tissue and then burr lightly using a DYONICS® ELITE Acromionizer Burr.

NOTE: During this stage, it is important to identify the location of the scapular spine so that the suprascapular nerve is not damaged at its base.

2. Humeral preparation involves using the 90-degree wand (Figure 4) to remove soft tissue and then a burr (Figure 5) to reveal bleeding cancellous bone.



AMBIENT SUPER  
TURBOVAC 90  
COBLATION Wand



DYONICS ELITE  
Acromionizer Burr



DYONICS INCISOR®  
Plus PLATINUM®  
Blades



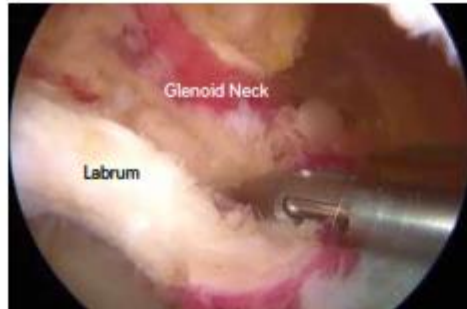

Figure 6

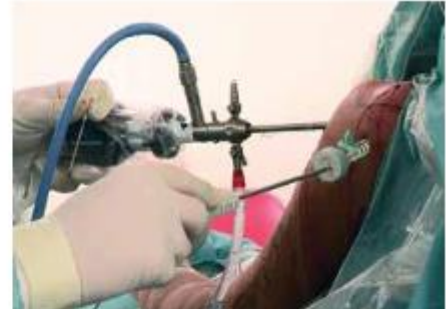

Figure 7

#### Glenoid Anchor Insertion

1. Through the posterior portal, a 1.8mm single or 2.8mm double-loaded Q-FIX® All-Suture Anchor is placed posteriorly in the glenoid neck at the superior aspect of the remaining infraspinatus, medial to the superior labrum. (Figures 6-8)
2. Through a separate stab incision, a second 1.8mm single-loaded or 2.8mm double loaded Q-FIX All-Suture Anchor is placed anteriorly at the most anterior aspect of the glenoid neck, medial to the superior labrum. (Figure 9)

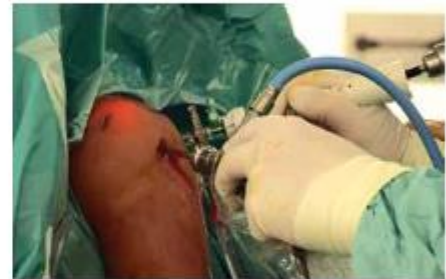

Figure 8

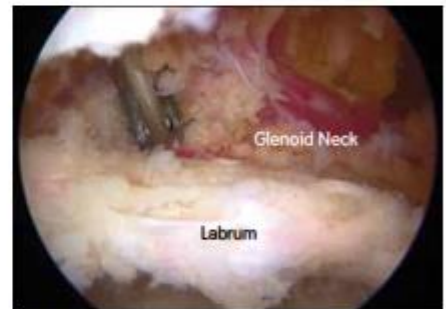

Figure 9



Q-FIX  
All-Suture Anchor

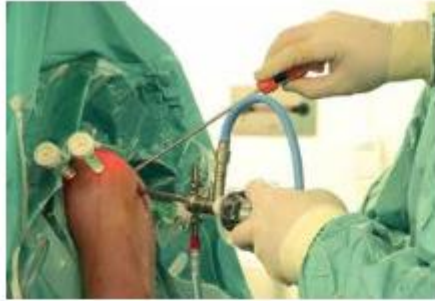

Figure 10

### Humeral Anchor Insertion

1. Through a separate stab incision, insert a 4.75mm HEALICOIL® REGENESORB® Suture Anchor with ULTRATAPE® Suture posterior, at the superior aspect of the infraspinatus (Figure 10 and 11). This anchor comes preloaded with one ULTRATAPE Suture and one ULTRABRAID® Suture.
2. Through a second anterior stab incision, place a second anchor anteriorly; just behind the biceps groove. (Figure 12)

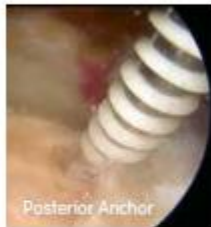

Figure 11

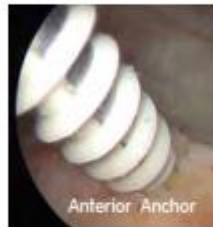

Figure 12

### Graft Measurement and Preparation

1. Tie a Mulberry Knot in a suture to assist in measuring the distance between the four anchors. (Figures 13-14)
  - These measurements are important as they will set the tension on your final graft.
  - Two graspers are used to measure the anchor distances. (Figure 15)
  - One grasper should grasp the knot of the suture and then be placed over one anchor; a second grasper then grasps the suture tight and places it over a second anchor.
  - The knot should then be released by the first grasper, the second grasper is then used to retrieve the suture and the distance between the grasper and the knot measured. (Figure 16)

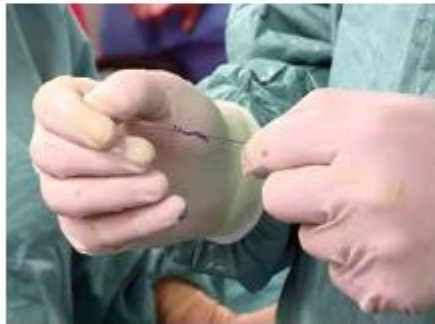

Figure 13

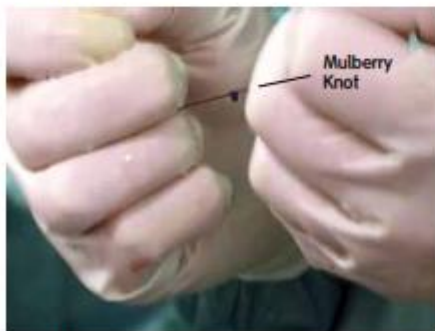

Figure 14

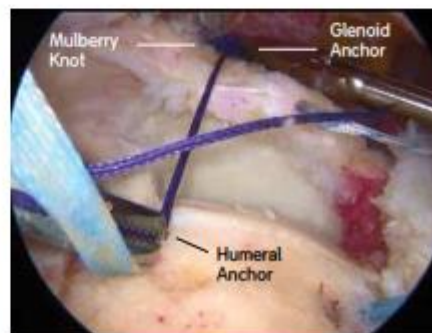


Figure 15

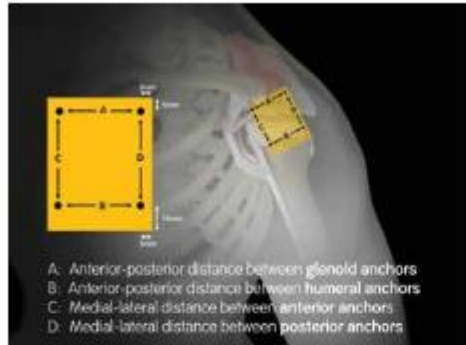


Figure 16



Figure 17

2. Measure the four distances between the anchors and draw-out on the back-table. (Figures 16-18)
  - Anterior-posterior distance between glenoid anchors (A)
  - Anterior-posterior distance between humeral anchors (B)
  - Medial-lateral distance between anterior anchors (C)
  - Medial-lateral distance between posterior anchors (D)
3. These measurements will provide an accurate placement of the holes in the graft through which you pass the sutures of the already placed anchors.

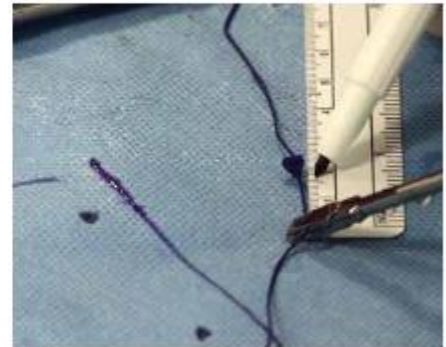

Figure 18



HEALICOIL®  
 REGENESORB Suture  
 Anchor Pre-loaded  
 with with ULTRATAPE®  
 Suture

Technique Guide 07057 V1

7

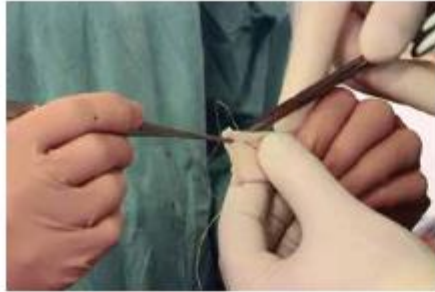

Figure 19

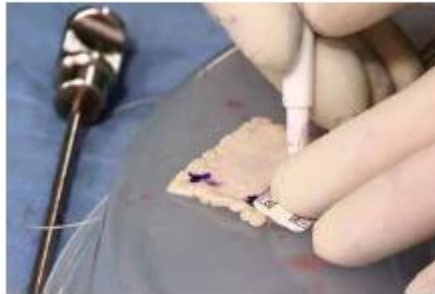


Figure 20

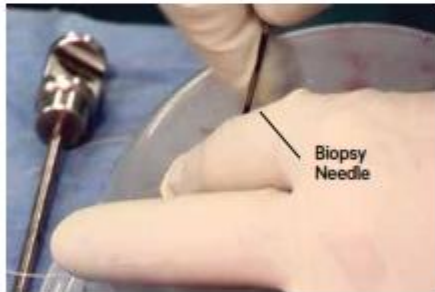


Figure 21

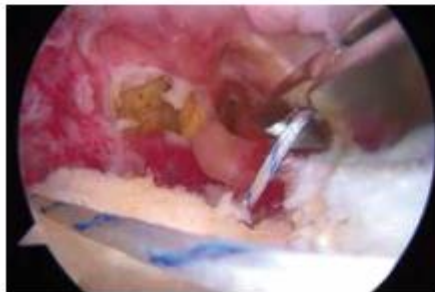

Figure 22

### Graft Sizing

1. The final graft size is based on the measurements obtained in the previous step, but enlarged to prevent suture cut-through and to ensure full foot-print coverage.
  - a. In the anterior-posterior direction, 5mm should be added to anterior and posterior anchor distanced (as seen in Figure 16).
  - b. In the medial-lateral direction, 5mm is added medially and approximately 15mm laterally. (Figure 16)
  - c. Use a folded human dermal collagen graft ensuring the porous side faces outwards on both the superior and inferior aspects of the graft.
  - d. Cut the graft to the correct size and use a Vicryl® suture to suture the graft together for easier manipulation. (Figure 19)
2. Mark the four points representing the anchor placement based on previous measurements and use a large arthroscopy or biopsy needle to create holes in the graft to assist suture passage. (Figures 20-21)

### Graft Insertion

1. Through the 10mm anterolateral cannula, use a suture grasper to retrieve two or three ULTRABRAID® Sutures (dependent on whether using single or double-loaded anchors) from each of the medial anchors in the glenoid. (Figure 22)


  
 CLEAR-TRAC®  
 COMPLETE  
 Disposable  
 Cannula Systems



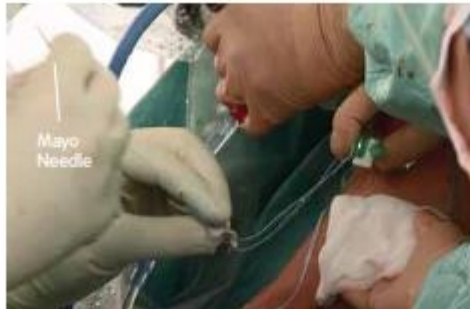

Figure 23

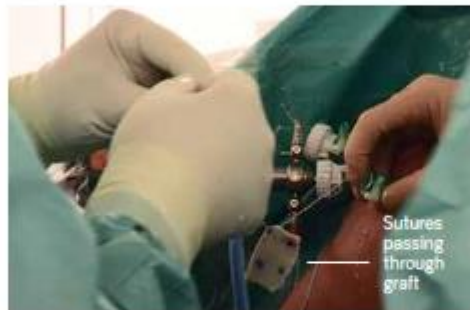

Figure 24

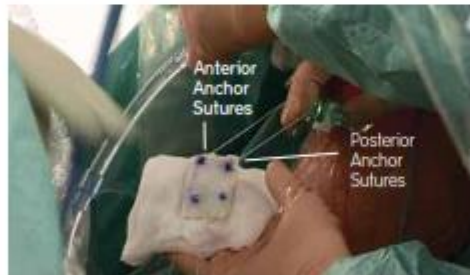

Figure 25

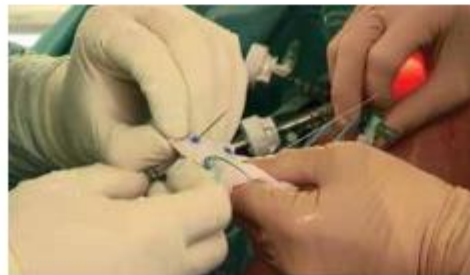

Figure 28

2. The sutures are passed through the graft at the pre-marked position using a mayo needle. (Figures 23-24)

- a. Ensure the sutures are kept separate in the four corners of the cannula.
- b. For the glenoid anchors, it is the antero-superior corner for the anterior glenoid anchor and postero-superior quadrant for the posterior anchor. (Figure 25)

3. All four humeral anchor sutures are retrieved and passed through the graft. (Figures 26-29)

- a. Ensure the sutures are kept separate in the four corners of the cannula.
- b. The anterior humeral anchor sutures are retrieved out the antero-inferior corner of the cannula and the posterior anchor sutures are retrieved out the posterior-inferior corner of the cannula.

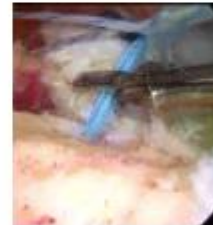

Figure 26

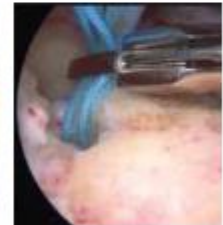


Figure 27

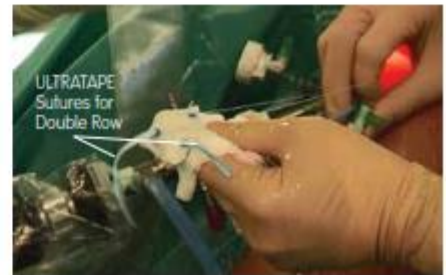

Figure 29

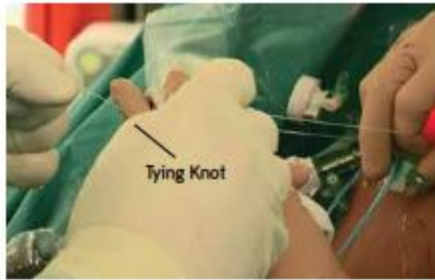

Figure 30

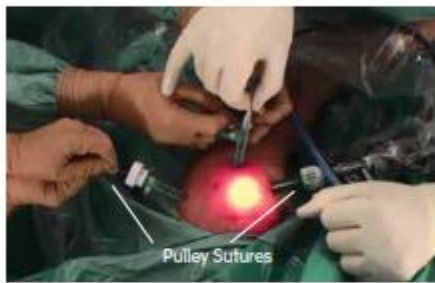

Figure 31

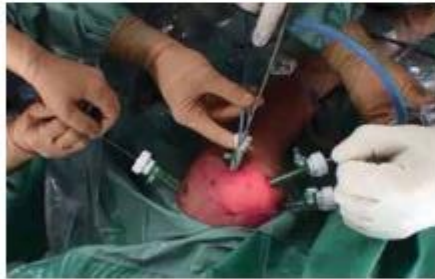

Figure 32

### Positioning and Securing the Graft on the Glenoid

1. Once all the sutures are passed through the graft, one suture from each glenoid anchor is tied to create a suture pulley and the ends are cut. (Figure 30)
2. The remaining suture from the pulley is then pulled in order to pass the graft into the shoulder. (Figure 31)
3. Graft passage down the cannula is assisted with the use of a grasper placed on leading edge of graft. (Figures 32-33) During graft passage the sutures from the humeral anchor in the inferior half of the cannula are kept taught.
4. Once the graft is in place (Figure 34), if using double loaded glenoid anchors, the remaining glenoid suture not through graft and its partner (through the graft) are tied through the anterior and posterior portals respectively.
5. The humeral sutures are then retrieved out the respective anterior and posterior cannulas, which helps to unfold the graft.
6. The remaining pulley glenoid sutures are then tied to secure the pulley suture. (Figure 35)

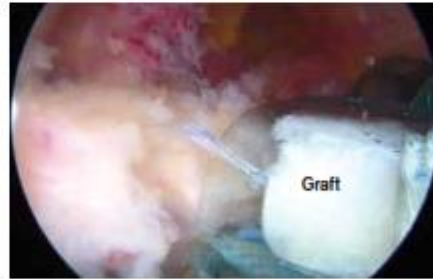

Figure 33

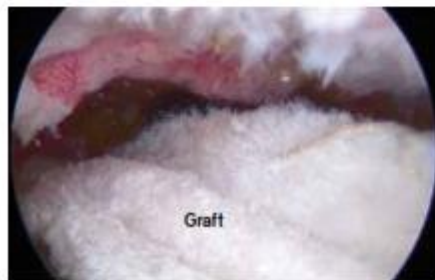

Figure 34

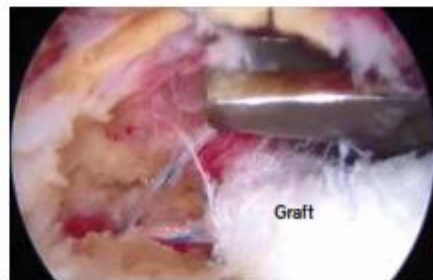

Figure 35

### Completing the Repair with Humeral Fixation

1. The sutures from each humeral anchor are then retrieved out of the anterolateral cannula and one suture from each anchor is tied with a surgeon's knot to create a pulley. (Figure 36)
2. The pulley suture is then reduced into the joint. (Figure 37)
3. The remaining humeral sutures are then tied arthroscopically in order to complete the humeral suture pulley. (Figure 38)
4. A double row suture bridge is then created with the ULTRATAPE® Sutures.
  - a. Pass one ULTRATAPE Suture from the anterior humeral anchor and one from the posterior anchor through a MULTIFIX® S ULTRA 5.5mm Knotless Suture Anchor for anterior lateral row fixation. (Figure 39) Repeat this step for the posterior lateral row fixation. (Figure 40)
  - b. Please note, during this stage, the arm is kept in 15-20 degree abduction.

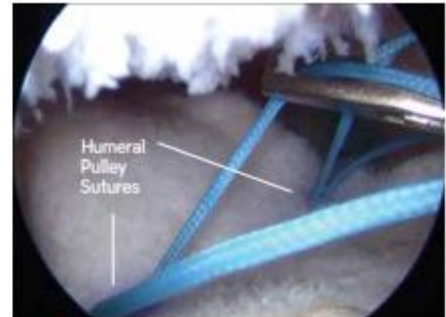


Figure 36

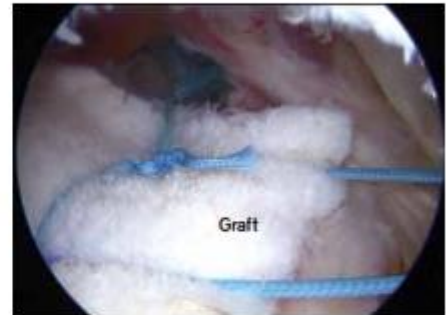


Figure 37

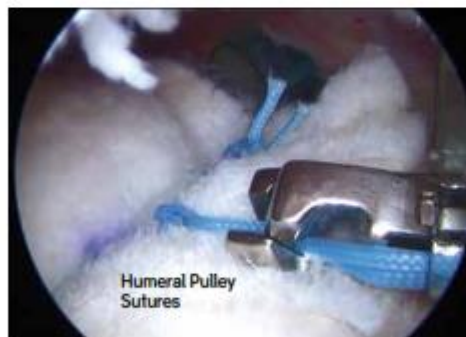


Figure 38

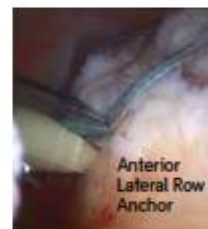

Figure 39

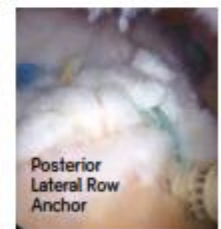

Figure 40



MULTIFIX® S ULTRA  
Knotless Suture  
Anchors



5. The residual infraspinatus is secured to the posterior aspect of the graft using a straight ACCU-PASS® Suture Shuttle (or FIRSTPASS® ST Suture Passer) and loose ULTRABRAID® Suture. (Figures 41-43)
6. The final construct is then visualized. (Figure 44)

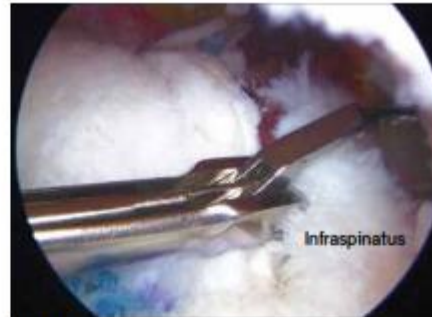


Figure 41

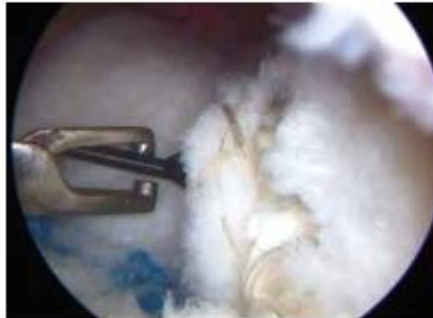


Figure 42

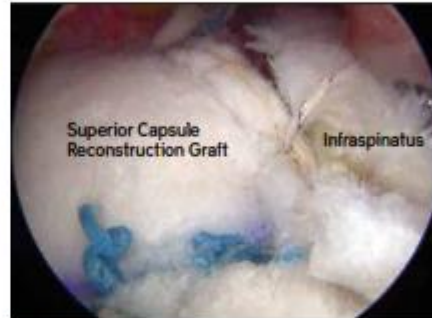


Figure 43

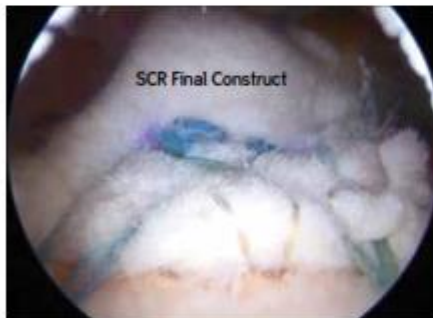

Figure 44



FIRSTPASS ST  
Suture Passer



ACCU-PASS Suture  
Shuttle (Straight)

## Ask The Expert...

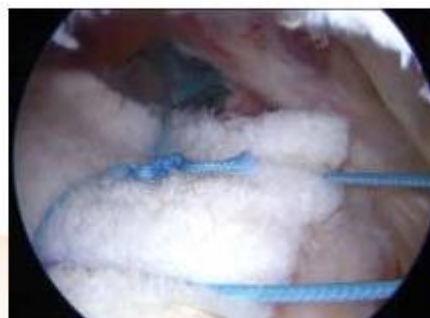Featuring Martyn Snow

Consultant Orthopaedic Surgeon at The Royal Orthopaedic Hospital, Birmingham, United Kingdom.

*The following comments are those of Martyn Snow, MD, containing a summary of medical techniques and opinions based upon his training and expertise in the field, along with his knowledge of Smith & Nephew's products. Smith & Nephew does not provide medical advice and recommends that surgeons exercise their own professional judgement when determining a patient's course of treatment.*

### **What has been your technique history for treating massive irreparable rotator cuff tears and can you briefly describe your evolution to Superior Capsule Reconstruction (SCR)?**

Prior to SCR, I would generally undertake a partial repair and dermal patch augmentation. After reading the article by Mihata et al. in 2013<sup>1</sup>, detailing the clinical results and mechanics of SCR I was interested in undertaking the technique given the impressive results. I have significant experience with the use of dermal patches and so decided to undertake the procedure using a double-layered dermal patch. Dermal patches have good mechanical strength and have been used in the shoulder



for many years, demonstrating good biological integration. Dermal grafts avoid the need to harvest fascia lata and the subsequent donor site morbidity. The decision to undertake an SCR can also be undertaken at arthroscopy once an irreparable tear is confirmed, this would be difficult with fascia lata, particularly in the beach chair position.

The use of all-suture anchors provide excellent fixation in the glenoid. Rotator cuff anchors were difficult to insert into the hard bone and traditional drill-in anchors have failed during graft delivery. Biomechanical literature has suggested that suture tape provides increased compression for the graft and reduced suture pull-through, when compared to standard #2 suture, in an attempt to improve healing.<sup>2,3,4,5</sup>

### **What are the primary advantages of SCR versus other more traditional procedures?**

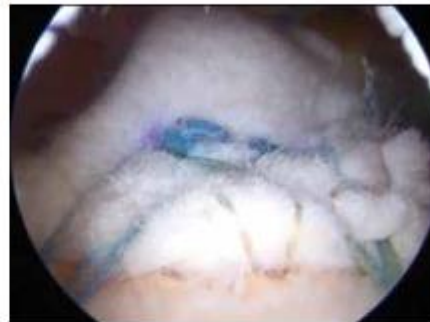We are still in the early stages of SCR and so its benefits versus alternative procedures such as partial repair and tendon transfer are still unknown. Given that the procedure does not rely on the repair of poor-quality tendon, SCR may offer more predictable results than a partial repair. There is no donor site morbidity with SCR compared to tendon transfer and the rehabilitation is more orthodox, negating the need for specialist input. SCR may potentially delay the need for reverse shoulder arthroplasty in young patients and therefore subsequent revisions.

### What are some general tips and tricks for anyone considering SCR?

Choosing the right patient is important. The ideal patient is the younger patient with irreparable tear who is a good rehabilitation candidate. The subscapularis should be intact or repaired if torn. I have seen the best results in patients who still have the infraspinatus at least partially attached. When first undertaking the technique, it is easier to use single-loaded anchors in the glenoid progressing to double loaded anchors when more experienced.

Measuring the anchor hole distances is also an important step and time should be taken to ensure this is done accurately.

Suture passage through the cannula and graft is the critical aspect of the surgery. Ensuring the sutures from the four anchors are kept to the four corners of the cannula is vital. This will prevent the sutures tangling and ensure easy graft passage. The top of the cannula should be removed so that the graft does not have to pass through the diaphragm of the cannula. The assistants thumb can be placed over the top of the cannula to ensure the sutures remain in the four corners of the cannula and that water loss from the shoulder is not excessive.



## References

1. Clinical Results of Arthroscopic Superior Capsule Reconstruction for Irreparable Rotator Cuff Tear. Mihata, Teruhisa et al. *Arthroscopy*. Volume 29, Issue 3, 459-470
2. Part I: Footprint contact characteristics for a transosseous-equivalent rotator cuff repair technique compared with a double-row repair technique. Park, Maxwell C. et al. *Journal of Shoulder and Elbow Surgery*, Volume 16, Issue 4, 461-468
3. A Biomechanical Comparison of the Pullout Strength of No. 2 FiberWire Suture and 2-mm FiberWire Tape in Bovine Rotator Cuff Tendons. Bisson, Leslie J. et al. *Arthroscopy*. Volume 26, Issue 11, 1463-1468
4. High-Tensile Strength Tape Versus High-Tensile Strength Suture: A Biomechanical Study Grandt, Ryan J. et al. *Arthroscopy*. Volume 32, Issue 2, 356-363
5. Abrasive Properties of Braided Polyblend Sutures in Cuff Tendon Repair: An in Vitro Biomechanical Study Exploring Regular and Tape Sutures. Deranlot, Julien et al. *Arthroscopy*. Volume 30, Issue 12, 1569-1573



## Ordering Information

To order the instruments used in this technique, call +1 800 343 5717 in the U.S. or contact an authorized Smith & Nephew representative. Prior to performing this technique, consult the Instructions for Use documentation provided with individual components – including indications, contraindications, warnings, cautions and instructions.

### Q-FIX® All Suture Anchor\*\*

Reference #	Description
25-1800	1.8mm Q-FIX® All-Suture Anchor
25-1810	Disposable Kit for 1.8mm Q-FIX Implant, includes Drill, Drill Guide and Obturator
25-2800	2.8mm Q-FIX All-Suture Anchor
25-2810	Disposable Kit for 2.8mm Q-FIX Implant, includes Drill, Drill Guide and Obturator

### HEALICOIL® REGENESORB Suture Anchor Pre-loaded with ULTRATAPE®

Reference #	Description
72203705	HEALICOIL REGENESORB 4.75 mm Suture Anchor with one ULTRATAPE Suture (Blue) and one #2 ULTRABRAID Suture
72203697	HEALICOIL REGENESORB 4.75 mm Suture Anchor with one ULTRATAPE Suture (Cobraid Blue) and one #2 ULTRABRAID Suture
72203708	HEALICOIL REGENESORB 5.5 mm Suture Anchor with one ULTRATAPE Suture (Blue) and one #2 ULTRABRAID Suture
72203801	HEALICOIL REGENESORB 5.5 mm Suture Anchor with one ULTRATAPE (Cobraid Blue) and one #2 ULTRABRAID Suture

### HEALICOIL REGENESORB Accessory Devices\*

Reference #	Description
72203709	HEALICOIL REGENESORB 4.75mm Threaded Dilator, reusable
72203710	HEALICOIL REGENESORB 5.5mm Threaded Dilator, reusable
72203951	HEALICOIL REGENESORB 4.75mm Threaded Dilator, disposable
72203952	HEALICOIL REGENESORB 5.5mm Threaded Dilator, disposable

### HEALICOIL PK Suture Anchor Pre-loaded with ULTRATAPE Suture\*

Reference #	Description
72203981	HEALICOIL PK 4.5mm Suture Anchor with one ULTRATAPE Suture (Blue)
72203982	HEALICOIL PK 4.5mm Suture Anchor with one ULTRATAPE Suture (Cobraid Blue)
72203983	HEALICOIL PK 5.5mm Suture Anchor with one ULTRATAPE Suture (Blue) and one #2 ULTRABRAID® Suture
72203984	HEALICOIL PK 5.5mm Suture Anchor with one ULTRATAPE Suture (Cobraid Blue) and one #2 ULTRABRAID Suture

### HEALICOIL PK Accessory Devices\*

Reference #	Description
72202621	3.8mm Tapered Awl, disposable
72201915	3.8mm Tapered Awl, reusable
72202633	4.5mm HEALICOIL/TWINFIX® ULTRA Threaded Dilator, reusable
72203634	5.5mm HEALICOIL/TWINFIX ULTRA Threaded Dilator, reusable

### MULTIFIX® S ULTRA Knotless Suture Anchors\*\*

Reference #	Description
72290001	MULTIFIX S ULTRA 5.5mm Knotless Suture Anchor
72290002	MULTIFIX S ULTRA 6.5mm Knotless Suture Anchor

### FIRSTPASS® ST Suture Passer\*\*

Reference #	Description
22-4038	FIRSTPASS ST Suture Passer, Self-Capture
22-4039	FIRSTPASS ST Suture Passer, Standard

### ACCU-PASS® Suture Shuttle\*

Reference #	Description
7210423	ACCU-PASS 45°, left, sterile
7210424	ACCU-PASS 45°, right, sterile
7210425	ACCU-PASS 45°, upbend, sterile
7210426	ACCU-PASS Straight, sterile
7210427	ACCU-PASS Crescent, sterile
72200419	ACCU-PASS 70°, upbend, sterile
72201361	ACCU-PASS monofilament, size #1, single pack, sterile (10 per box)

**CLEAR-TRAC® COMPLETE Disposable Cannula System\***

Reference #	Description
72200902	8.5mm x 90mm Threaded Cannula, with disposable obturator, green, sterile
72200903	8.5mm x 72mm Threaded Cannula, with disposable obturator, green, sterile
72200904	8.5mm x 45mm Threaded Cannula, with disposable obturator, green, sterile
72200905	7.0mm x 72mm Threaded Cannula, with disposable obturator, grey, sterile
72200907	5.5mm x 72mm Threaded Cannula, with disposable obturator, blue, sterile
72200908	5.5mm x 45mm Threaded Cannula, with disposable obturator, blue, sterile
72200909	4.5mm x 72mm Threaded Cannula, with disposable obturator, purple, sterile

**CLEAR-TRAC COMPLETE Reusable Obturators\***

Reference #	Description
72200910	8.5mm x 90mm Reusable Obturator (4.3mm cannulation), green
72200911	8.5mm x 72mm Reusable Obturator (4.3mm cannulation), green
72200915	7.0mm x 72mm Reusable Obturator (4.3mm cannulation), grey
72201796	5.5mm Reusable Obturator (4.3mm cannulation), blue

**CLEAR-TRAC Threaded Cannula with Cannulated Obturator\***

Reference #	Description
7207197	CLEAR-TRAC Threaded Cannula, 10 mm I.D., 76 mm long with 4.0 mm cannulated obturator, white, contains latex

**DYONICS® Shaver Blades and Burrs\***

Reference #	Description
72203013	DYONICS® INCISOR® Plus PLATINUM® 4.5mm Blade
72203519	DYONICS INCISOR Plus PLATINUM 5.5mm Blade
72200724	4.0 mm ELITE Acromionizer
72200725	5.5 mm ELITE Acromionizer

**AMBIENT® SUPER TURBOVAC® 90 COBLATION® Wand\*\***

Reference #	Description
ASHA4250-01	AMBIENT SUPER TURBOVAC 90 IFS
ASH4250-01	SUPER TURBOVAC 90 IFS
ASC4250-01	SUPER TURBOVAC 90

**T-MAX Beach Chair Positioner\***

Reference #	Description
7210551	T-MAX Beach Chair Positioner – includes Chair and Pad Assembly, Head Positioning Assembly, Table Leg Assembly, Knee Bolster and Lateral support (2 units).
7210552	Adjustable Arm Board
7210554	North American Rail Clamps (2 units)
72203415	Non-Operative Arm Board
72203318	Adjustable Lateral Support

**T-MAX Disposable Accessories\***

Reference #	Description
7210559	Disposable Face Masks (case of 8)

**SPIDER2 Limb Positioner\***

Reference #	Description
72203299	SPIDER2 Limb Positioner
72203301	SPIDER2 Battery Pack
7210570	Piggy Back Connector (2 per box, required for all sterile procedures)

**SPIDER2 Disposable Accessories\***

Reference #	Description
72203300	Switch Drape (case of 20)
7210571	Beach Chair Shoulder Connection Bar (2 units)
7210573	Shoulder Stabilization Disposables Kit (case of 12)

**Indications for Use**

**HEALICOIL REGENESORB, MULTIFIX S ULTRA, and Q-FIX** have the following Indications for Use:

**Shoulder:**

- Rotator cuff tear repairs
- Bankart lesion repair
- SLAP lesion repair
- Acromioclavicular separation repairs
- Capsular shift or capsulolabral reconstructions
- Biceps tenodesis
- Deltoid repairs

**Caution:** U.S. Federal law restricts these devices to sale by or on the order of a physician.

Supporting healthcare professionals for over 150 years

\*Manufactured by:  
Smith & Nephew, Inc.  
150 Minuteman Road  
Andover, MA 01810 USA

\*\*Manufactured by:  
ArthroCare Corporation  
7000 West William Cannon Drive  
Austin, TX 78735 USA

www.smith-nephew.com  
T +1 978 749 1000  
US Customer Service: +1 800 343 5717  
International Customer Service: +1 978 749 1140

\*Trademark of Smith & Nephew.  
©2016 Smith & Nephew.  
All Trademarks Acknowledged.  
Printed in USA, 07057 V1, PN 83423 Rev. A. 10/16



# APPENDIX C: Subacromial Balloon Spacer Insertion Technique Guide

## INTRODUCTION

Massive Rotator Cuff tears present both a physical and biological challenge to the surgeon attempting to repair them. The tear is considered irreparable according to pre-procedural MRI or intra-operative assessment. The Cuff tissue is often retracted and degenerated. The muscle tissue can be atrophied and with fat infiltration.

While the average rate of Rotator Cuff re-tear post repair is approximately 20-40%, failure rates of massive tears can approach 100%. Surgeons are looking for a solution which will reduce significantly their patients pain.

By having the InSpace™ Balloon implanted between the acromion and the humeral head, a space is created between the bone structures; allowing for smooth and frictionless gliding. The Balloon was initially designed for chronic, massive, non-reparable Rotator-Cuff tears; enabling leverage of other muscles. The Balloon may be inserted arthroscopically, or potentially, even with a mini-open procedure.

The InSpace™ Balloon surgical technique is only five steps of fast and elegant procedure. Still a surgeon who is considering an arthroscopic approach needs to be familiar with several such techniques as well as trained in the InSpace™ Balloon procedure.

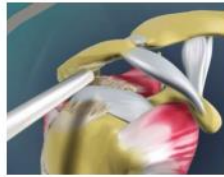## Positioning and Set-up

A standard arrangement for arthroscopic Rotator Cuff repair is used. Either beach chair or the lateral decubitus position is appropriate.

Besides the arthroscopic instrument set several other items are required (not part of the implant package):

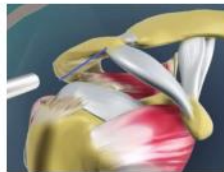
- \* Luer-lock 50cc Syringe
- \* Extension tube + 3 way valve
- \* Arthroscopic probe
- \* Saline 0.9%

1 Adams, J. E.; Zobitz, M. E.; Reach, J. S., Jr.; An, K. N.; and Steinmann, S. P. Rotator cuff repair using an



### Step 1

Perform a standard subacromial arthroscopy to estimate the tendon condition and to ensure it is an irreparable Rotator Cuff tear. Mild debridement may be required to clean the synovial tissue and clear the subacromial space.



### Step 2

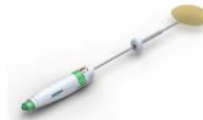The InSpace™ Balloon comes in 3 sizes:

- \* Small (40x50mm)
- \* Medium (50x60mm)
- \* Large (60x70mm)

Measure the subacromial space by using an arthroscopic probe. Measurements required to select Balloon size are:

- \* width of the acromion from anterior to posterior
- \* Distance from greater tuberosity (lateral point) - 2cm medial to superior glenoid rim.

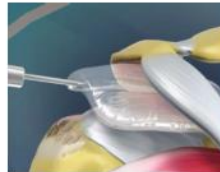Select InSpace™ Balloon according to your measurement.



### Step 3

Prepare the inflating system in advance. Fill syringe with saline heated to 40 degrees Celsius, and remove any air bubbles (in syringe, extension tube and valve).

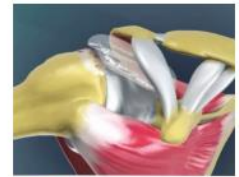
Introduce the InSpace™ delivery system through a true lateral port. The Balloon should be advanced over the glenoid rim and 2cm over the Rotator Cuff tendon stump. After final positioning of the delivery system pull back the protecting sheath and expose the Balloon. Re-verify Balloon position in the subacromial space.



### Step 4

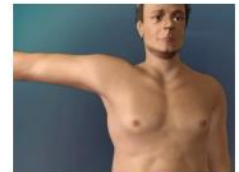Connect the extension tube to the rear side of the delivery system (Luer-lock connector). Inflate the Balloon to full volume (check table below). Keep the valve open and let saline flow back into the syringe. Do not over inflate the Balloon to avoid increasing subacromial pressure. When satisfied with Balloon volume seal the Balloon – see recommended inflation volumes according to Balloon size below.

Size	Width (mm)	Length (mm)	Max. volume (cc)	Recommended Volume (cc)
Small (REF 0127)	40	50	15-17	9-11
Medium (REF 0128)	50	60	22-24	15-16
Large (REF 0129)	60	70	40	22-24



### Step 5

For sealing and detachment of the Balloon push the red safety button forward and turn the green knob till full detachment. Remove the delivery system and go through full ROM. Verify that the Balloon is stable in situ, and cannot be subluxated or dislocated. If the Balloon can be dislodged, replace the Balloon.



## Rehabilitation

The use of a post operative sling is recommended for comfort for one week. Patients may begin full Active Assisted and Passive Range of Motion (ROM) immediately as pain allows and early active ROM at waist level without restriction. Overhead activity is avoided for 6 weeks. A typical post-operative Physician or Therapist monitored Progressive Resistance Exercise program, including therabands and full closed chain scapular stabilization exercises, is recommended to maximize functional results.

## INTRODUCTION

The InSpace™ Balloon System is designed to create a physical barrier (spacer) between tissues in the subacromial space.

- The InSpace™ Balloon System is provided sterile.
- The physiological solution that should be used with the InSpace™ Balloon System is not supplied with the system.
- The InSpace™ Balloon is latex free.

## INDICATIONS

The InSpace™ biodegradable Balloon implant is used as a spacer to reduce friction between the acromion and humeral head or Rotator Cuff. The indications for the InSpace™ Rotator Cuff Balloon include: Scarred or torn tendons due to trauma or degradation; absence of tendon/muscle, or non-functional tendon/muscle; and ruptured tendon. The device is single use and biodegrades within 12 month.

## CONTRAINDICATIONS

- The InSpace™ Balloon Implant should not be implanted into areas with active or latent infection or signs of tissue necrosis.
- The InSpace™ Balloon Implant should not be implanted if the patient has an allergy to the Balloon material (PLA and epsilon-caprolactone).

**DISCLAIMER:** The InSpace™ balloon has approved for marketing in EU but not yet in USA. This material should be considered informational only and does not constitute an offer to sell in any jurisdiction in which this product is not yet permitted to be sold.

## WARNINGS AND PRECAUTIONS

- Prior to using the InSpace™ Balloon System for the first time, users must be trained by a company representative in the use and deployment of the Balloon system.
- The risks and benefits of implanting the InSpace™ Balloon System in patients with blood coagulation disorders, compromised immune systems, severe chronic diseases such as heart failure, cirrhosis, chronic renal failure or any other conditions that would compromise healing should be carefully considered.
- Do not re-sterilize or reuse the Balloon or the deployer. These parts are intended for single use only.
- Non-functional instruments should not be used and should be returned to Orthospace™.
- Do not use any part of the InSpace™ Balloon System beyond the indicated expiration date.
- Do not use the InSpace™ Balloon System if the package is opened or damaged, as sterility may be compromised.
- Do not use the InSpace™ Balloon System if the Humidity Indicator for the 40% Humidity level has turned from a light blue to a purple color.

## STORAGE

Until use, the Orthospace™ Balloon System should be stored in a clean and dry area at 0-29°C temperature.

## USE OF ORIGINAL PRODUCTS

The components of the Orthospace™ Balloon System are designed for specific use and to complement each other. No system components may be replaced by a product from another manufacturer even if the other product or part is comparable or identical to the original product in appearance and dimensions. The material used from other manufacturers, any structural alterations resulting from use of products from another source and/or impurities of the material as well as minor differences of adjustment between the implant and instruments introduce unforeseen risks to the subject and user.



Ortho Space Ltd. 21 Atir Yeda St., Kfar Saba, 44643, Israel  
Tel +972-9-7880080 • Fax +972 (9) 7731756  
www.orthospace.co.il • info@orthospace.co.il



REV 2

OrthoSpace  
**InSpace™**  
New Solution for Rotator cuff injury  
Surgical Technique

## Curriculum Vitae

### **Supriya Singh**

Department of Surgery, Division of Orthopedic Surgery  
Western, University  
London, ON

#### **EDUCATION**

---

- 2017-Present      **University of British Columbia**  
*Department of Surgery*  
Branch for International Surgical Care
- Graduate Certificate in Global Surgical Care
- 2016-2017      **Western University**  
*Department of Surgery*  
London, Ontario
- Master's of Surgery Program
- 2014-Present      **Western University**  
*London Health Sciences Centre*  
London, Ontario
- Orthopedic Surgery Residency Training Program (PGY-4)
- 2010-2014      **Western University**  
*Schulich School of Medicine and Dentistry*  
London, Ontario
- Doctor of Medicine
- 2006-2010      **Queen's University**  
*Life Sciences Subject of Specialization Program*  
Kingston, Ontario
- Bachelor of Science Honors (*graduated with distinction*)

## AWARDS AND QUALIFICATIONS

---

- 2017 **DR. ROBERT ZHONG DEPARTMENT OF SURGERY RESEARCH AWARD**
- Best resident research paper presentation (\$500)
- 2016 **SANDY KIRKLEY AWARD**
- Top clinical science research paper presentation at the annual Orthopedic Surgery Resident Research Day (\$1000)
- 2016 **DAVID OSMOND AWARD FOR BIOMECHANICAL ASSESSMENT OF MASSIVE ROTATOR CUFF TEAR**
- Research grant (\$25,000)
- 2016 **ONTARIO GRADUATE SCHOLARSHIP**
- Based on academic excellence for students applying for a graduate program (\$15,000)
- 2016 **BEST OVERALL RESEARCH PRESENTATION**
- Awarded at the Annual Pediatric Surgery Research Day
- 2016 **BEST CLINICAL RESEARCH PRESENTATION**
- Awarded at the Annual Department of Pediatric Research Day
- 2015 **CLASS OF MEDS '49 AWARD FOR EXCELLENCE IN TEACHING BY RESIDENTS**
- Nomination by clinical clerks for excellence in teaching by a junior resident
- 2014 **DR. GLEN S. WITHER MEMORIAL AWARD**
- Awarded to the final year medical student who has demonstrated the highest attributes of the physician-integrity, concern for patients, compassion and a devotion to the profession.
- 2014 **DR. ROB TINGLEY CLASS OF '95 DEVELOPING COUNTRIES AWARD**
- Convocation award established to recognize life-altering international elective experience
- 2014 **DRS. JAMES AND LESLIE ROURKE CONVOCATION AWARD IN MEDICINE**
- Awarded annually to a graduating student who has made an outstanding personal contribution to bettering the lives of others through volunteer work and humanitarian acts while maintaining a high academic standing.

- 2014 **THE UNITED WOMEN OF LONDON GLOBAL HEALTH AWARD**
- Awarded for exceptional and extraordinary contributions to global health at Schulich School of Medicine and Dentistry, locally and nationally.
- 2014 **ROCHE SCHOLARSHIP**
- Awarded to a graduating student for work in the final phase of the course; proficiency, progress and leadership evaluated on the general lines of the Rhodes Scholarship
- 2013 **LEBOLDUS AWARD FOR OUTSTANDING CLINICAL CLERK**
- Awarded annually to an outstanding clinical clerk, selected by Council of Faculty
- 2013 **JIM SILCOX AWARD**
- Awarded to a medical student who, in the opinion of the Hippocratic Council and the Student Affairs Committee, has contributed most significantly to the lives of student, faculty and the community.
- 2013 **CERTIFICATE OF MERIT**
- Highest standing award in undergraduate surgical education
- 2012 **MEDS 2014 OUTREACH AWARD**
- Meds 2014 Kickstart Outreach Program Award (\$200).
- 2012 **GLOBAL HEALTH OPPORTUNITIES AWARD**
- Western University award for global health outreach work (\$1000)
- 2012 **OFFICE OF GLOBAL HEALTH AWARD**
- Global health award for pursuing international electives and fundraising projects (2 x \$1500)
- 2011 **RBC ROYAL BANK SCHOLARSHIP**
- Annual national scholarship for 6 medical students (\$15 000 award)
- 2010 **QUEEN'S UNIVERSITY DEAN'S HONOUR LIST**
- Queen's University dean's honour list for above 80% average [2006-2010]
- 2010 **FRENCH CERTIFICATE OF COMPETENCE**
- University level competence in French language based on oral, written and comprehension examinations and academic French course credits received
- 2008 **QUEEN'S UNIVERSITY PRINCIPAL SCHOLARSHIP**
- Queen's University Entrance Scholarship received for above 95% average

2006 **FRENCH IMMERSION DIPLOMA**

- Graduated from high school with French immersion diploma, officially bilingual

**LANGUAGE COURSES**

- University Level Spanish, Italian, German, Punjabi and Swahili [2008-2012]

**TRAINING:**

- Advanced Cardiovascular Life Support (ACLS)
- Advanced Trauma Life Support (ATLS)
- Principles of Surgery Course/Surgical Foundations (Royal College of Physicians and Surgeons of Canada)
- AO North America Trauma Course – Basic Principles of Fracture Management
- Resident as a Teacher Bootcamp – Two day intensive teaching skills workshop
- University Level Training on Community Development, Leadership for Diversity and Social Identities and Peer Support – National Coalition Building Institute

**CLINICAL INTERESTS AND RESEARCH**

---

- ❖ **Hope: A Resident's Experience Providing Rural Health Care in Tanzania**
  - Published in the Canadian Orthopedic Association Global Surgery Spring Bulletin (May 2017)
  - Published in the Canadian Society of Orthopedic Technologists Bulletin (July 2017)



- ❖ **Use of Incisional Negative Pressure Wound Therapy in Orthopedic Surgery**  
(Supervisor: Dr. Rasoulinejad, Orthopedic Surgery)
  - Review Article submitted to Neural Regeneration Research, March 2017
  
- ❖ **An InVitro Study of Massive Rotator Cuff Tears and Repair Kinematics: Comparing Subacromial Balloon Spacer with Superior Capsular Reconstruction**  
(Supervisors: Drs. Athwal and Johnson, Hand/Upper Limb Orthopedic Surgery)
  - Current Master's of Surgery Project (2016-2017)
  
- ❖ **The Impact of Education on Post Operative Opioid Consumption: A Prospective, Randomized Controlled Trial on Minimizing Opioid Risk Exposure in Orthopedic Surgery**  
(Supervisors: Drs. Clarke, Sanders, Macleod and Lawendy, Orthopedic Surgery)
  - Podium presentation at Department of Orthopedic Surgery Resident Research Day, London, ON, October 2016
  - Podium presentation at Canadian Orthopedic Association Annual Conference, Ottawa, ON, June 2017
  - Podium presentation at Canadian Orthopedic Resident Association Annual Conference, Ottawa, ON, June 2017
  - Abstract published in Ortho Evidence as Best Evidence in Foot and Ankle COA 2017 ACE Report [myorthoEvidence.com/acereports/report/9708](http://myorthoEvidence.com/acereports/report/9708)
  - Abstract published in Journal of Bone and Joint November 2016
  - Podium presentation at Department of Surgery Research Day, London, ON, June 2017
  
- ❖ **Evaluation of Primary Caregiver's Perceptions on Home Trampoline Use**  
(Supervisors: Drs. Bartley, Cashin and Carey, Pediatric Orthopedic Surgery)
  - Poster presentation at Department of Orthopedic Surgery Resident Research Day, London, ON, October 2015
  - Podium presentation at Annual Pediatric Surgery Research Day, London, ON, February 2016
  - Podium presentation at Annual Department of Pediatric Medicine Research Day, London, ON, May 2016
  - Podium presentation at Annual Department of Surgery Research Day, London, ON, June 2016
  - Podium presentation at Canadian Orthopedic Association Annual Meeting, Quebec City, QC, June 2016
  - Abstract published in Journal of Bone and Joint Surgery December 2016. [http://www.bjjprocs.boneandjoint.org.uk/cgi/content/abstract/98-B/SUPP\\_21/100](http://www.bjjprocs.boneandjoint.org.uk/cgi/content/abstract/98-B/SUPP_21/100)
  - Paper submitted to Journal of Pediatrics and Child Health, June 2017

- ❖ **Massive Transfusion in Pediatric Trauma Patients: frequency, patient profile, and clinical outcomes**  
(Supervisor: Dr. Neil Merritt, Pediatric General Surgeon)
  - Paper published in Journal of Pediatric Surgery/Injury
  - Poster presented at Trauma Association of Canada Conference, Whistler, BC, 2013
  - Poster presented at CSCI/CITAC Annual Conference, Ottawa, ON, 2013  
(Canadian Investigator Trainee Association of Canada)
  
- ❖ **MSK Medicine Clinical Skills Videos**  
(Supervisor Dr. Macaluso, Department of Physiatry)
  - Musculoskeletal physical examination videos and website design  
<http://mskmedicine.com/clinical-skills/>
  - Medical school curriculum project 2012-2013
  
- ❖ **What Motivates Medical Students to learn Anatomy?**  
(Supervisor: Dr. Marjorie Johnson, Department of Anatom)
- Poster Presentation at the American Association of Anatomy Annual Conference, San Diego, CA, April 2012
  
- ❖ **Our Journey of a Thousand Miles; why we should care: Reflections from a summer in Tanzania**  
(Supervisor: Dr. Mhando, Arusha, Tanzania)
  - Poster and Podium Presentation at Transcending Borders: Western University Global Health Conference, London, ON, May 2012

## **VOLUNTEER AND EXTRACURRICULAR EXPERIENCE**

---

### **INTERNATIONAL OUTREACH PROJECTS [2010-present]:**

- ❖ Non-Governmental Organization  
NYOTA, Non Profit Youth Organization for children in Tanzania, Africa –  
Founder and sponsoring education for over 50 street youth
- ❖ Pre-departure Training Leader (Ethics of travelling abroad)
- ❖ Hungry For Change Gala - Guest Speaker (Poverty and Youth Action)
- ❖ International Medical Elective (Arusha, Tanzania, December 2013)



- ❖ **Med Outreach Tanzania (July-August 2011)**  
Group of 8 medical, dental and nursing students who travel to Arusha, Tanzania to work in rural medical clinics and hospitals promoting primary health care prevention.
- ❖ **Tanzania Project (August 2011-2014)**  
During medical school worked towards personally sponsoring and sending 12 street children to school and providing them with food, clean water and shelter for 4 years. Volunteered at Nkoaranga Orphanage, Karama House (HIV orphanage) and Sunrise of Life Street Children Organization and fundraised over \$8000 for children's schooling and medical needs
- ❖ **Canadian Association of Medical Teams Abroad (CAMTA)**  
Orthopedic surgical resident volunteer on annual mission to Quito, Ecuador with CAMTA team from Edmonton, Alberta. Provided surgical care and public health education to local community. (February 2017)
- ❖ **Team Broken Earth London**  
Initiated London, ON first Broken Earth Team for orthopedic surgical outreach work in Port Au Prince, Haiti. (November 2017)
- ❖ **Canadian Orthopedic Association Global Surgery Committee**  
Resident representative for global outreach work for COA. Work to promote global surgery opportunities to orthopedic residents across Canada. (2017-2018)

## **EXTRACURRICULAR INVOLVEMENT:**

### **❖ LEADERSHIP ROLES**

#### **2017-2018 PARO General Council**

- Elected as a student representative for Western University on the professional association of residents of Ontario

#### **2017-2018 Sous-Chief Resident**

- Served as a student representative on our department committee meetings, took on administrative responsibilities in resident education

- 2017-2018 **Quality Improvement for Long-Term Care Facilities after Hospital Discharge (Victoria Hospital, Orthopedic Surgery)**
- Senior resident on quality improvement team to help facilitate medication reconciliation post hospital inpatient discharge to reduce medication incidents in long-term care homes
- 2016-present **Surgical Wellness Committee**
- Student leader on committee, representing orthopedic surgical residents
- 2016-present **Women in Orthopedic Mentorship Group**
- Founder and organizer of mentorship group between our female orthopedic surgeons and residents at London Health Sciences Centre
- 2015-2016 **Junior Chief Resident**
- Served as a student representative on our department committee meetings
- 2014-present **Women in Surgery Group**
- Served in a leadership role organizing events to coordinate mentorship program between medical students and surgical residents and staff
- 2014-present **Medical Student Education**
- Served in a leadership role organizing events in coordination with surgery interest group and post graduate education department (simulation sessions, suturing, anatomy dissection sessions, surgery bootcamp, etc...)
- 2015-2016 **PGME Transition to Residency**
- Served as a student representative on curriculum development for transition from medical school to residency training